JPSIM Journal of Pakistan Society of Internal Medicine

Case Report

Young Female who Presented with Hemoptysis

Sadaf Yousaf, Muhammad Irtiza Irshad

Arif Memorial Teaching Hospital/Rashid Latif Medical College, Lahore

Abstract

Goodpasture syndrome is a rare autoimmune disorder characterized by pulmonary hemorrhage and glomerulonephritis, due to formation of auto-antibodies against type 4 collagen protein.In it's typically form pulmonary haemorrhage presents before, and more often the initial presentation, before the onset of end-stage renal disease (ESRD) secondary to Chronic GN. The development of pulmonary hemorrhage after progression to ESRD is an uncommon and unique phenomenon as represented in this case study. This is a case of 20-year-old unmarried female from Narowal, a known case of ESRD secondary to chronic glomerulonephritis, who presented with a three-day history of progressive dyspnea (NYHA Class III) and left-sided chest pain, along with light headedness and palpitations. Systemic inquiry revealed malaise, low-grade fever, and anorexia. There was no significant family history; she belonged to a low income house hold. Lastly there she had no known allergies, with no significant travel history and history of completed childhood vaccination. This case represents the peculiarity with the atypical presentation of pulmonary Hemorrhage after the progression to ESRD in Goodpasture syndrome, it is a rare and underreported occurrence. This finding shows the importance of prompt recognition and multidisciplinary management cases complex as these. This report contributes to the growing understanding of Goodpasture syndrome's varied clinical course and outcomes in ESRD patients.

Keywords: Goodpasture Syndrome, Pulmonary Hemorrhage, End-Stage Renal Disease, Glomerulonephritis.

How to cite this:

Yousaf S, Irshad MI. Young Female who Presented with Hemoptysis. J Pak Soc Intern Med. 2025;6(4): 376-379

Corresponding Author: Prof. Sadaf Yousaf, **Email:** drsadafyousaf@yahoo.com

Received: 25-05-2025 **Revised:** 20-08-2025 **Accepted:** 10-11-2025 **DOI:** https://doi.org/10.70302/jpsim.v6i4.2570

2709-8729/© 2025 The Author(s). Published by JPSIM on behalf of Pakistan Society of Internal Medicine, Lahore, Pakistan.
This is an open access article under the CC BY 4.0 license https://creativecommons.org/licenses/by/4.0/

Introduction

Goodpasture's or anti-glomerular basement membrane (GBM) disease is classically characterized by the presence of circulating autoantibodies directed against the non-collagenous domain of the α3 chain of type IV collagen, targeting glomerular and alveolar basement membranes, and associated with rapidly progressive crescentic glomerulonephritis, with alveolar hemorrhage in over half the patients. However, there are increasing examples of variants or atypical presentations of this disease, and novel therapeutic options have been proposed, which nephrologists should be aware of. The pathophysiology of this condition has been understood through molecular analysis of the antibody–antigen interactions and the use of human leucocyte antigen-transgenic animals, while the association of anti-GBM antibodies with anti-neutrophil cytoplasm antibodies and their combined impact on disease phenotype is increasingly recognized, providing some insights into the basis of glomerular damage and autoimmunity.[1]

This report highlights an unusual presentation of Goodpasture syndrome in a young female with established ESRD on maintenance hemodialysis, who developed life-threatening pulmonary hemorrhage requiring aggressive intervention. The case underscores the need for awareness of atypical disease manifestations in patients with ESRD.

Case Presentation

This is a case of 20-year-old, unmarried female from Narowal, Pakistan, she is known case of ESRD secondary to chronic glomerulonephritis (GN), presented to the nephrology outpatient department on February 13, 2024, with complaints of sudden-onset progressive shortness of breath and left-sided chest pain for three days. Dyspnea was of graded III, according to NYHA Classification; it was associated with lightheadedness and palpitations. Whereas, chest pain was dull in nature and moderate in severity. Pain was non-radiating, non-shifting, aggravated by physical activity, and relieved by rest. The patient reported systemic symptoms of malaise, low-grade fever, and anorexia but denied hemoptysis, weight loss, or skin rash at presentation.

There was no significant family history; she belonged to a low income house hold. Lastly there she had no known allergies, with no significant travel History and history of completed childhood vaccination.

Her past medical history revealed a diagnosis of ESRD at age 18 due to chronic GN, attributed by prolonged NSAID abuse and hakeem medications due to recurrent throat infections. At the time of her initial presentation, two years ago, her kidneys were noted to be shrunken with loss of corticomedullary differentiation on ultrasonically, so, discussion of not going through with renal biopsy was taken. She had been on regular hemodialysis ever since her diagnosis.

Examination: On general physical examination, the patient was pale, with whitish discoloration of her nails, dirty sclera, pedal edema, and hyper-pigmented skin creases.

Abdomen: Soft, slight tenderness in the epigastrium and left hypochondrium, with no palpable viscera.

Respiratory: Normal vesicular breathing, with reduced air entry and vocal resonance in the right basal area.

Cardiovascular: Presence of S1, S2, and a flow murmur was noted.

CNS: Patient was alert and oriented with a GCS score of 15/15.

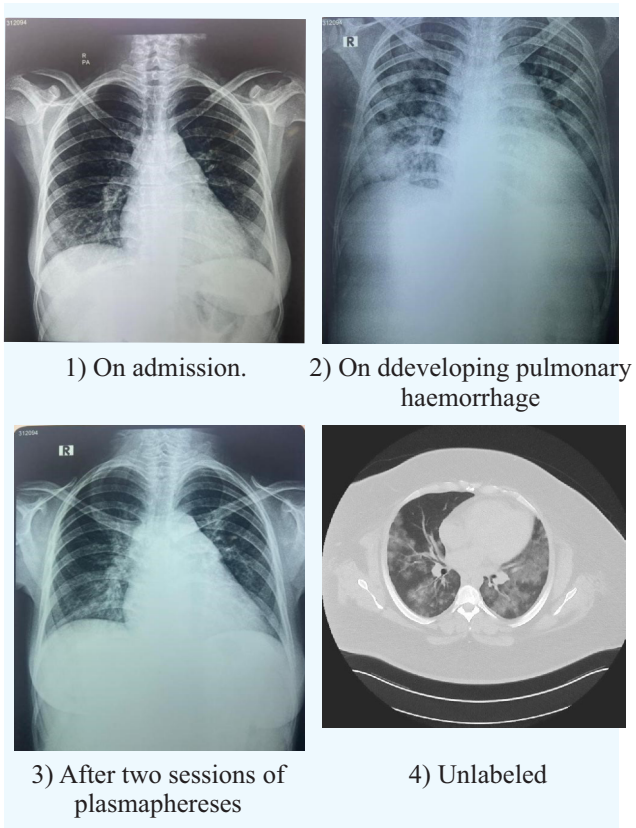

1) On admission. 2) On ddeveloping pulmonary haemorrhage

3) After two sessions of plasmaphereses 4) Unlabeled

Figure I: *Follow up radiology Findings*

Investigations: Base-line work-up revealed severe anemia of Hb 7 g/dL, hyperkalemia of K+ 6.0 mmol/L, and proteinuria. The X-ray chest in PA plain, on admission, did not reveal any evidence of pulmonary hemorrhage. ECG showed tall T waves consistent with her hyperkalemia.

Hospital Course: On the day of admission, the patient was managed for hyperkalemia using standard de-potassium protocols. However, on the second day of admission, where things went smooth, she developed new-onset hemoptysis, worsening chest pain, and hypoxia with a declining SpO_2 levels. X-ray chest in PA view was repeated at this stage showed signs of pulmonary hemorrhage and patient was stepped up to the level of critical care. Given her acute deterioration of clinical condition and clinical suspicion of pulmonary-renal syndrome, plasmapheresis was initiated before the results of autoimmune markers were available.

Autoimmune markers, including anti-GBM and ANCA, later returned positive, confirming Goodpasture syndrome. Plasmapheresis was performed in two sessions three days apart which led to a marked improvement in her clinical picture and stabilized her respiratory symptoms. Anemia was corrected using packed cell transfusions, and a concurrent respiratory infection was treated with moxifloxacin, initially oral and later via intravenous route. Lung biopsy was proposed to confirm the etiology of pulmonary hemorrhage but was declined by the family.

Outcome and Follow-Up: After stabilizing her condition, she was discharged on 21st Feb, 2024. At the time of her discharge, initial presenting complaints of shortness of breath and chest pain were significantly improved and resolved. As evident by her repeated lab workup; Hemoglobin levels increased from 7 g/dL to 11.8 g/dL, this rise was brought by packed cell transfusion during dialysis sessions. Total leukocyte count (TLC) decreased from 20×10^9/L to 7×10^9/L which reflects the resolution of infection brought by use of moxifloxacin. Serum creatinine levels improved from 3.0 mg/dL to 2.0 mg/dL after two sessions of dialysis. Serum electrolytes were within normal limits at the time of discharge.

During her hospital stay, as a part of base line investigation in high risk patient viral markers for hepatitis C and B were checked, Hepatitis C result came out to be positive and a treatment plan was oriented for her and in her 3 month follow up, according to her PCR for quantitative Hep C RNA was negative indicating a successful treatment.

The patient was advised to continue regular hemodialysis and scheduled for follow-up in the nephrology department. She and her parents were properly informed about her condition and possibility of re-occurrence

and danger signs to be watchful for.

Discussion

Goodpasture syndrome (GS) is a rare disease, the morbidity of which is estimated to be 0.5-0.8 per million per year. Hemorrhage is the most serious complication in renal biopsy. Despite the fact that both GS and hemorrhage after renal biopsy are rare, it has not been reported that they are likely to occur in the same patient.[2]

Although Goodpasture syndrome is well-recognized for its renal and pulmonary manifestations, the occurrence of pulmonary hemorrhage in ESRD is exceedingly rare. Few cases have been documented in the literature, such as those in Clinical Nephrology and BMJ Case Reports, which describe delayed pulmonary manifestations in patients already on hemodialysis.[2,3] These cases underscore the potential for reactivation or persistence of pathogenic anti-GBM antibodies, possibly triggered by secondary factors such as infections or systemic stressors.

Plasmapheresis remains the cornerstone of therapy for Goodpasture syndrome, especially in cases involving pulmonary hemorrhage. Studies in Therapeutic Apheresis and Dialysis and Nephrology Dialysis Transplantation have demonstrated the efficacy of plasmapheresis in rapidly removing circulating anti-GBM antibodies as it halts the disease progression.[4,5] Immunosuppressive agents such as corticosteroids and cyclophosphamide are commonly used in conjunction; however, their use must be carefully balanced in patients with co-morbidities.

The coexistence of Hepatitis C in this patient further complicated the clinical picture. Autoimmunity and viral infections often interact in complex ways as with Hepatitis C is a known risk factor to exacerbate autoimmune processes. Autoimmunity Reviews discuss the therapeutic challenges of managing Goodpasture syndrome in the presence of Hepatitis C, it emphasizes the importance of carefully timed antiviral therapy.[6]

Reports from Kidney International and Journal of Autoimmunity suggest that outcomes in Goodpasture syndrome vary depending on the timing of diagnosis and initiation of therapy. Early plasmapheresis and immunosuppression are associated with improved survival and reduced morbidity.[7,8] The resolution of pulmonary symptoms and improvement in laboratory markers in this patient after two sessions of plasmapheresis is consistent with findings in the literature.

As per this case, it is unique because it demonstrates a delayed pulmonary manifestation of Goodpasture syndrome in a dialysis-dependent patient, successfully managed with early initiation of plasmapheresis prior to confirmatory autoimmune markers. The absence of pulmonary signs on initial imaging and the development of hemorrhage later highlight the importance of vigilance in such patients. Moreover, the concurrent management of Hepatitis C with antiviral therapy without exacerbating the autoimmune process.

In conclusion, this case adds to the existing literature by providing insights into the management of delayed pulmonary hemorrhage in Goodpasture syndrome and underscores the importance of early therapeutic intervention even in the absence of immediate diagnostic confirmation.

This case represents a peculiar case of Goodpasture syndrome, normally after fibrosis and sclerosis of kidneys the antigenetic stimuli reduces and incidence of pulomary hemorrages decreases, but as evident by this case, a patient of ERSD with shrunken kidneys, developing this devastating complication.

Conclusion

This case highlights the diagnostic and therapeutic challenges of managing Goodpasture syndrome in patients with ESRD especially in low budget set-ups and with financial restrains. This patient's unique presentation of delayed pulmonary hemorrhage, successful management with plasmapheresis initiated before confirmatory autoimmune markers, and concurrent treatment of Hepatitis C exemplify the importance of a multidisciplinary approach. Early intervention, vigilant monitoring, and individualized care are crucial in improving outcomes in such complex cases. The findings also emphasize the need for heightened awareness among clinicians to recognize atypical manifestations of Goodpasture syndrome, especially in high-risk populations. There also represent the importance of renal biopsy and immunological study to get ahead of this disease.

Conflict of Interest: None

Funding Source: None

Authors' Contribution

SY: Conceptualization of the project

MII: Design of the work.

SY, MII: Data acquisition, analysis, or interpretation.

MII: Draft the work.

SY: Critical review of important intellectual content.

Both authors approve the version to be published.

Both authors agree to be accountable for all aspects of the work.

References

1. Scott R Henderson, Alan D Salama, Diagnostic and management challenges in Goodpasture's (anti-glomerular basement membrane) disease. Nephrol Dialysis Transplant. 2018;33(2):196-202.
2. Li WL, Wang X, Zhang SY, Xu ZG, Zhang YW, Wei X, et al. Goodpasture syndrome and hemorrhage after renal biopsy: A case report. World J Clin Cases. 2020; 8(2):404-9.
3. Shah DS. Pulmonary Hemorrhage and Dialysis: A Case of Goodpasture's in a Young Adult. BMJ Case Reports. 2017;.https://doi.org/10.1016/j.transci. 2010. 01.004.
4. Boardman EA, Sohail S, Yadavilli R. Goodpasture's disease with late presentation of renal abnormality and anti-GBM autoantibody. BMJ Case Rep. 2017; doi: 10.1136/bcr-2016-218705.
5. Levin M, Rigden SP, Pincott JR, Lockwood CM, Barratt TM, Dillon MJ. Goodpasture's syndrome: treatment with plasmapheresis, immunosuppression, and anticoagulation. Arch Dis Child. 1983;58(9):697-702.
6. Zignego AL, Gragnani L, Giannini C, Laffi G. The hepatitis C virus infection as a systemic disease. Intern Emerge Med. 2012;7(Suppl 3):201-8.
7. Kim YO, Choi JY, Park JI, Yoon SA, Yang CW, Kim KH. A case of Goodpasture's syndrome with massive pulmonary hemorrhage. J Korean Med Sci. 2000; 15(1): 99-102.
8. Jiao LP, Fan JF, Sun Q, Shen Y. Plasma exchange in Goodpasture syndrome associated with Turner's syndrome: A case report. Afr Health Sci. 2012;12(4):572-5.