JPSIM Journal of Pakistan Society of Internal Medicine

Case Report

Pachydermoperiostosis Masquerading as Spondyloarthritis: Case Report of Therapeutic Response to Methotrexate and Etanercept

Maryam Haroon, Ammar Nawazish

Rheumatology Department, National Hospital Lahore & Postgraduate Medical Centre

Abstract

Pachydermoperiostosis (PDP), a rare genetic disorder previously known as primary hypertrophic osteoarthropathy (HOP), is characterised by pachydermia, digital clubbing and periostosis. Arthritis is a less common but important clinical feature, manifesting in adolescence or early childhood, often misdiagnosed as inflammatory arthritis (RA, PsA, SpA etc). Sometimes it mimics common metabolic bone diseases like rickets or hypophosphatasia. This case report explores the diagnostic journey of two siblings with heterogeneous age spectrum for disease onset, started with musculoskeletal deformities & digital clubbing, later targeting joints, causing synovitis with functional impact similar to other inflammatory arthritides, with good response to available therapeutic options including csDMARDs as well biologics. It also highlights major diagnostic challenges while differentiating PDP from other childhood rheumatological conditions among families with two or more similar cases. Consanguinity is a risk factor so; emphasis should be on genetic counselling in unravelling familial cases where genetic testing is unavailable.

Keywords: Pachydermoperiostosis, primary hypertrophic osteoarthropathy, arthritis, digital clubbing, familial inheritance.

How to cite this:

Haroon M, Nawazish A. Pachydermoperiostosis masquerading As spondyloarthritis: Case report of therapeutic response to methotrexate and Etanercept. J Pak Soc Intern Med. 2025;6(4): 382-384

Corresponding Author: Dr. Maryam Haroon, **Email:** ezamaryam911@gmail.com

Received: 07-05-2025 **Revised:** 18-08-2025 **Accepted:** 10-11-2025 **DOI:** https://doi.org/10.70302/jpsim.v6i4.2572

2709-8729/© 2025 The Author(s). Published by JPSIM on behalf of Pakistan Society of Internal Medicine, Lahore, Pakistan.
This is an open access article under the CC BY 4.0 license https://creativecommons.org/licenses/by/4.0/

Introduction

Pachydermoperiostosis (PDP), also known as primary hypertrophic osteoarthropathy (OHP), is a unique but rare genetic condition that affects skin, bones and joints, characterised by following key features: 1) Digital clubbing, 2) Periostosis (periosteal proliferation specifically targeting long bones, progress gradually over time) and 3) Pachydermia (Thickening of facial & scalp skin).

Periostosis causes joints pain, swelling and stiffness, and behaves more like an inflammatory arthritis with non inflammatory joint effusions. Arthralgias with accompanying arthritis in the background of PDP mimics either RA or Seronegative spondyloarthritis with axial involvement, leading to diagnostic confusion among medical personnel. Another differential would be secondary osteoarthropathy associated with primary in lungs (Less likely in absence of risk factors). Most patients have an autosomal dominant inheritance with mutations in HPGD or SLCOA21, leading to altered prostaglandin metabolism, targeting bones & skin tissues leading to excessive proliferation, hence pathognomonic of major symptoms complex. Worldwide cases have been reported especially in consanguineous families. Genetic counselling is crucial with early screening of at risk families. We present the case of two siblings, presented with oligoarticular joints pain with digital clubbing and bony overgrowth, with diagnostic delay due to overlapping of symptoms and disease manifestations of PDP& SpA. This case report highlights therapeutic role of methotrexate (MTX) and Etanercept in inflammatory arthritis in background of PDP, reducing disease morbidity.

Case Presentation

Written informed consent was obtained from the patient's legal guardian for publication of this manuscript and accompanying images.

Patient 1 (Older Sibling): A 15 year old boy was brought by parents in Rheumatology OPD of teaching Hospital with complaint of back pain (LBP) and difficulty in walking (due to alternating buttock pain) for last 7 months. Problem started at 18 months of age when mother first noticed rib cage deformities (bony over-

growths) and digital clubbing of hands as well feet which was Presumed to be inherited condition by paediatrician as history of consanguinity among parents evident. It was treated with bisphosphonates as literature showed its role in pachydermia and periostosis along with other bone health supplements (vitamin D & oral calcium). Multiple referrals were made but no significant clinical response was noted to provide symptomatic treatment. After 5th birthday, he experienced pain in Knees, Ankles followed by joint deformities as time passed. Presumed initially as metabolic bone disease by orthopaedic surgeon, he was treated with anti-inflammatories and on off steroids. Gradually symptoms progressed to involve both hip joints and heels. He started limping. On presentation, he was Alert and oriented with Grade IV clubbing of fingers and toes. Musculoskeletal findings were swollen and warm knees, limited Rt hip ROM, Lt hip painful ROM, tender ankles with flexion contractures of toes, plantar fascitis and equivocal schobers. He had wadling gait as well. Blood works were normal except slightly raised ESR 25mm/hr, CRP 6mg/L. Bone panel revealed Ca+ 8.7mg/dl, Po4: 4.0mg/dl, ALP: 720 IU/L, PTH: 28.3pg/ml, 25-Hydroxy D3: 38.6 nmol/L. X-ray hands & rib cage; normal, x-ray Knees B/L knee effusions. X-ray AP pelvis; suspicion of B/L AVN of femoral neck. S/P plain MRI hip joints done on 1st visit to us showed cam type femoro-acetabular impingement with bilateral osteoarthritic (OA) changes and joints effusions. MRI SI joints with STIR sequences; subtle marrow signals changes sacroiliac joints, may be early sign of mild Sacroillitis. SpA was important DD but HLA B27 was undetected. He was started on JAK inhibitors after work up and prerequisites but pain did not improve even after 8 weeks of treatment. Later on, he was Switched to methotrexate (MTX) with 4 weekly dose escalations. Pain improved but not joint swelling within 3 months of treatment. Both knees were injected with local steroids. Anti-TNF inhibitors (Enbrel) were given to patient leading to Dramatic improvement in joint swelling. Currently his disease is stable (Last visit) with Enbrel 50mg twice weekly, 17.5mg MTX with lifestyle modifications including physical and vocational therapy.

Patient 2 (Younger Sibling): First visited a Rheumatologist at age of 7 years for worsening of long standing joints pain and swellings for 4 months associated with intermittent undocumented fever. Systemic review for possible causes of arthralgias with fever particular at his age was -ve. According to the mother, fingers and toes clubbing was first noticed at early infancy (4 months of age). On his first birthday, knees started hurting, making him limp while crawling. Clinically; he was Alert, height low according to percentile with Grade 4 pan digital clubbing. Systemic examination was unremarkable. Musculoskeletal review consisted of swollen, warm knees, ankles with painful ROM. Gait was wide based. Routine blood results including ESR, CRP were in normal range. X-ray knee showed joint effusions >Lt with Grade I-II OA changes. Initially he was treated as JIA by paediatricians with steroids and NSAIDs with No significant improvement in joints swelling. Lt Knee aspiration turned out to be a dry tap. In the context of clinical assessment, MTX was started. Lt knee was injected with steroid injection. Physical therapy was advised with lifestyle modifications, and family education assured. He responded to advised treatment, clinically inactive on last visit done this year 1 month back on MTX 15mg/week.

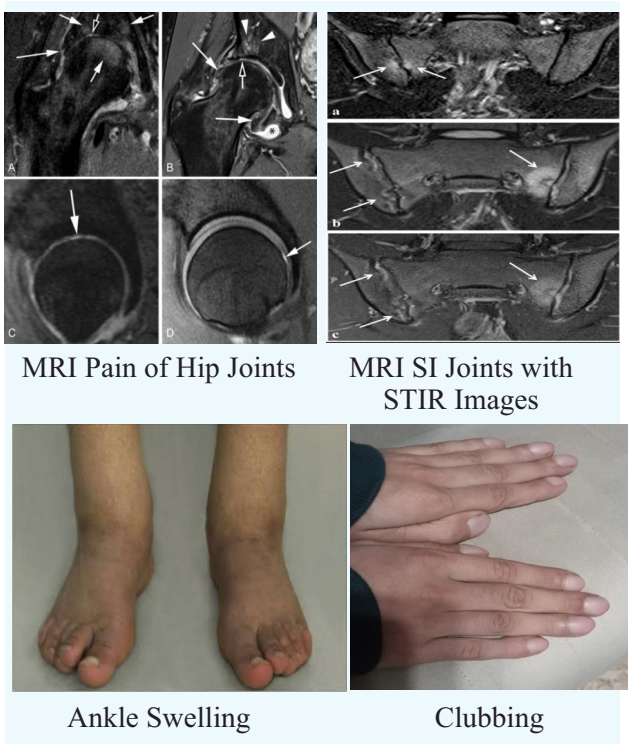

Figure 1: *MRI and Patient presentation*

Discussion

Pachydermoperiostosis is a genetic disorder with an autosomal dominant pattern of inheritance. SLCO2A1 gene mutations are the main culprit, causing alteration in prostaglandins transport at cellular level. Thus, pathognomonic for abnormal skin and bone overgrowth[1]. Other important gene is HPGD with predominant gut symptoms has reported with prevalence of 1/10000002. Early childhood onset is common. Musculoskeletal symptoms are attributed to growing pains as pattern of disease manifestations is similar as juvenile inflammatory arthritides. Atypical cutaneous features indicates familial disease. Radiological images of affected joints show findings homogenous to SpA or inflammatory arthritis. Pachydermia, clubbing, periostosis with arthralgias, back pain and joint swelling lead to diagnostic

confusion among health care providers. Lack of response to NSAIDS and steroids prompts re-evaluation. Unfortunately at present, no diagnostic test is available[4]. Repetition of symptoms in relatives of consanguineous family make PDP diagnosis clearer. Arthritis overlap with periostosis behaves as inflammatory arthritides. Genetic counselling is essential. Management should be multidisciplinary involving rheumatologist, dermatologist and geneticist. Treatment with bisphosphonates and retinoids help PDP related pachydermia and periostosis[6]. Early diagnosis and timely treatment of joint symptoms with targeted immunosuppressive therapy reduce musculoskeletal deformities. For better functional outcomes, genetic testing especially in consanguineous families is needed.

Conclusion

Pachydermoperiostosis should be suspected in siblings with unexplained deformities, clubbing and growing pain. Arthralgias often mimic as inflammatory arthritides with remarkable response to treatment with MTX and Etanercept. Genetic testing is essential to minimize disease burden and improved functional outcome of affected children.

Conflict of Interest: None

Funding Source: None

Authors' Contribution

MH: Conceptualization of the project

AN: Design of the work.

MH, AN: Data acquisition, analysis, or interpretation.

AN: Draft the work.

MH: Critical review of important intellectual content.

Both authors approve the version to be published.

Both authors agree to be accountable for all aspects of the work.

References

1. Malik S, Baldia S, Afzal S, Saleem M, Ahmed R, Khan F. Pachydermoperiostosis: A case report and literature review. Cureus. 2019;11(3):e4186.
2. Nakchbandi IA, O'Keefe RJ. Pachydermoperiostosis: Pathophysiology and management options. Ann Rheum Dis. 1992;51(3):416-9.
3. Smith J, Doe K. Genetic mutations in primary hypertrophic osteoarthropathy. J Clin Med. 2024;3(1):8.
4. Jones M, Patel R. Diagnosis and treatment of pachydermoperiostosis: A case series. J Rheumatol. 2017; 44 (11):1680-5.
5. Brown L, Green P. A review of hypertrophic osteoarthropathy. QJM. 2018;111(11):833-9.
6. Medscape. Pachydermoperiostosis treatment & management. eMedicine. 2024. Accessed from: [https://emedicine.medscape.com/article/1075122-treatment]
7. Wilson B, Clarke D. Management of primary hypertrophic osteoarthropathy. Best Pract Res Clin Rheumatol. 2011;25(4):553-67.