JPSIM Journal of Pakistan Society of Internal Medicine

Case Report

Common Variable Immunodeficiency Presenting as Tuberculous Meningitis in a Young Asian Female- A Case Report

Uzma Aftab,[1] Seemab Abid,[1] Mariya Ahsan,[1] Samar Saleem,[2] Saima Ambreen,[1] Iqra Ashraf[1]

[1]Holy Family Hospital, Rawalpindi Pakistan, [2]Rawalpindi Teaching Hospital, Rawalpindi Pakistan

Abstract

Common variable immunodeficiency disorders (CVID) represent primary immune deficiencies that manifest with complications involving infections and inflammation, primarily due to deficiencies in antibody production and occasionally affecting cellular immunity. A 20-year-old woman presented with symptoms of persistent mild fever, headache, sudden sensitivity to light, and a confused mental state, without any history of seizures. Since infancy, she had experienced recurrent airway and gastrointestinal infections. On examination, she was vitally stable with a temperature of 100.4°F, Glasgow Coma Score (GCS) of 9, positive signs of meningeal irritation, and bilateral coarse crackles on chest auscultation. Laboratory findings and cerebrospinal fluid (CSF) analysis were suggestive of tuberculous meningitis, and anti-tuberculous treatment was initiated. Further workup was performed considering the patient's susceptibility to repeated infections, and she was diagnosed with common variable immunodeficiency based on the Ameratunga criteria. Her condition markedly improved after the administration of parenteral immunoglobulin therapy. Delayed diagnosis of common variable immunodeficiency, often due to diverse patient presentations, can have grave outcomes as in this case; therefore, a history of recurrent infections should never be overlooked until a definite cause is established.

Keywords: Common Variable Immuodeficiency, CVID, Tuberculosis, Immunology, Meningitis

How to cite this:

Aftab U, Abid S, Ahsan M, Saleem S, Ambreen S, Ashraf I. Common Variable Immunodeficiency Presenting as Tuberculous Meningitis in a Young Asian Female- A Case Report. J Pak Soc Intern Med. 2026;7(1): 77-80

Corresponding Author: Dr. Uzma Aftab, **Email:** uzmaaftab308@gmail.com

Received: 30-11-2025 **Revised:** 15-01-2026 **Accepted:** 20-02-2026 **DOI:** https://doi.org/10.70302/jpsim.v7i1.2616

2709-8729/© 2026 The Author(s). Published by JPSIM on behalf of Pakistan Society of Internal Medicine, Lahore, Pakistan.
This is an open access article under the CC BY 4.0 license https://creativecommons.org/licenses/by/4.0/

Introduction

Common Variable immunodeficiency (CVID), a syndrome of primary immunodeficiency, is characterized by a substantial decrease in serum immunoglobulin (IgG), immunoglobulin (IgA), and/or immunoglobulin (IgM), as well as a poor or impaired response to vaccination. The precise mechanism of CVID pathogenesis is not fully understood and patients have been found to have abnormal B-cell and T-cell counts, as well as defects in the innate and adaptive immune systems. While abnormalities in plasma cells are the hallmark immunological defect associated with CVID, changes to other subsets of B cells are also frequently observed. Various genetic mutations at nuclear, surface and cytoplasmic level have been recently linked with CVID pathogenesis1. The documented occurrence of Common Variable Immunodeficiency (CVID) varies significantly across countries, with an average of about 0.676 per 100,000 individuals. The prevalence tends to be higher in countries categorized as having a "high" Human Development Index (HDI) and vice versa due to limited awareness and lack of systematic documentation of CVID cases in the latter[2]. As the name implies, the clinical spectrum of CVID has marked variation including recurrent respiratory tract infection, chronic lung disease, gastrointestinal disorders, autoimmunity, lymphoproliferative disorders, and malignancy.[1]

Meningitis can manifest in individuals with Common Variable Immunodeficiency, but it is considered infrequent. The typical route of meningitis acquisition involves the transmission of bacteria through the bloodstream into the cerebrospinal fluid (CSF), expedited by an immunological deficiency.[3] Various case reports have been presented that describe a range of bacteria, fungi and viruses as the culprits of meningitis in CVID patients.[2,3] To our best possible knowledge and literature search across available database, no case of CVID presenting with Tuberculous meningitis has previously been reported.

Here we present a case report of young female presen-

ting with tuberculous meningitis as a complication of undiagnosed Common Variable Immunodeficiency, highlighting the need for timely diagnosis and management of this disease to minimize the possible adverse sequelae.

Case presentation

A 20 years old female presented in the medical emergency of our department in tertiary care hospital of Rawalpindi, Pakistan with complains of low grade non-documented fever and headache for 10 days, altered sensorium along with photophobia for 1 day with no history of any episode of fits. Her past medical history revealed multiple episodes of respiratory tract infections, frequent episodes of watery, non-bloody, non-foul smelling diarrhea and repeated episodes of acute otitis media since the age of 5 months leading to hospital admissions more than three times every year. She was born at term via spontaneous vaginal delivery as the first child of second degree consanguineous marriage. She was vaccinated according to national immunization program and had achieved developmental milestones at appropriate age. However, she could not continue her education beyond primary grade owing to frequent infections requiring stay at local hospitals. There was no positive family history of any genetic disorder and she belonged from a low socio-economic background.

On examination, patient was vitally stable except temperature of 100.4 F with a Glasgow Coma Score of 9, positive kerning and Brudzinki sign, pallor conjunctiva and grade 3 clubbing in nails. There were coarse crackles in bilateral lower lung lobes on chest auscultation. There was no lymphadenopathy and rest of systemic examination was unremarkable. Laboratory investigations showed leukocytosis (Total Leukocyte Count 24000/microliter). Written informed consent was taken and lumbar puncture was performed after excluding raised intracranial pressure via fundoscopy and CSF analysis revealed a turbid fluid with Total Leukocyte Count 1000/µL, lymphocytes 65%, proteins 132 mg/dl, glucose 42 mg/dl; favouring Tuberculous meningitis. MRI brain showed diffuse smooth pachymeningeal and leptomeningeal enhancement along with bilateral maxillary and ethmoid sinusitis. Treatment with Anti tuberculous therapy (Ethambutol hydrochloride 275mg, Rifampicin 150mg, Isoniazid 75mg, Pyrazinamide 400mg) and steroids was commenced and patient showed significant clinical improvement after three days.

Based on previous history of patient, further work-up was done for recurrent respiratory tract infections and chronic diarrhea. High Resolution CT chest was performed which showed right middle lung lobe collapse and bronchiactatic changes in bilateral lung lobes predominantly in peri-hilar location and lower lobes as illustrated in Figure 1. Anti Tissue Transglutaminase - IgA and Ig G for coeliac disease were negative but duodenal biopsy showed moderate villous atrophy with increased intraepithelial lymphocytes and no evidence of giardia organism; suggestive of CVID related enteropathy. Ultrasound abdomen was unremarkable. Immunological studies revealed markedly reduced levels of IgG (<1.6 g/L) and IgA (<0.3 g/L) immunoglobulins while IgM levels were mildly reduced (0.4 g/L). Flow cytometry studies showed mild elevation of cytotoxic T-lymphocytes and normal levels of B cells supportive of qualitative defect in B lymphocytes. Other laboratory investigations included normal levels of Anti-Nuclear antibody, negative Coomb's test, normal Thyroid function tests, negative titer of Brucella antibodies, and normal urine analysis.

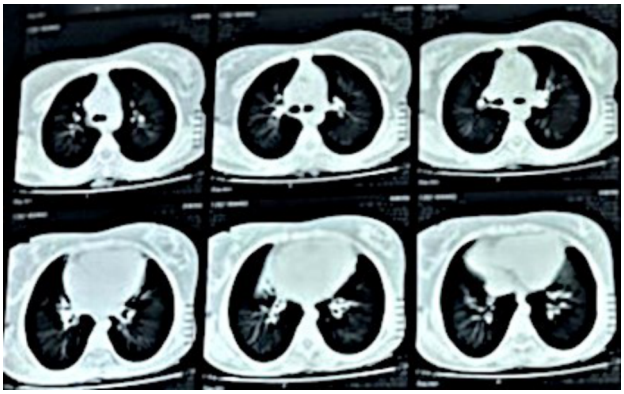

Figure 1: *High Resolution CT chest showing bronchiectatic changes in bilateral lungs predominantly in perihilar region*

Based on history, examination and laboratory findings, diagnosis of Common Variable Immunodeficiency (CVID) was established and patient was started on intravenous Immunoglobulin therapy in the dose 400mg/kg monthly. Her parents were then trained for giving subcutaneous injection and patient remained free from any infection in the subsequent six months, the longest disease free interval she had since birth.

Discussion

Common variable immunodeficiency (CVID) is characterised by loss of antibody generation. Although, CVID is the primary immunodeficiency with highest prevalence, it is still a rare entity and its occurrence in developing countries is lower than in industrialized world[1]. The diagnostic criteria of Ameratunga et al. (2013) for CVID was used to establish the diagnosis of Common Variable immunodeficiency in this patient4. This case meets all three major criteria namely IgG levels less than 5g/L, age greater than 4 years and no other identifiable cause of hypogammaglobulinemia. Moreover, clinical features attributable to failure of immune system including recurrent infections, bronchiectasis and

chronic sinus disease were also present. Supportive laboratory evidence of concomitant reduced levels of IgA and IgM levels was also seen in this patient.

While cellular immunity is only mildly impaired in CVID, humoral immunity is typically weakened, hence, making the patients more susceptible to bacterial infections than fungal and viral illnesses.[5] Not only this, there is also a marked increase in risk of developing malignant and lymphoproliferative disorders.[6] Macrophages and CD4+ T cells, along with the formation of granulomas, are evidently the cornerstones of immunological defense against Mycobacterium tuberculosis. Although, every component of immune system participates in defense against this pathogen, the role of antibody- mediated immune responses is not clearly understood. Hence, patients with qualitative and quantitative defects in B-cell function are not particularly susceptible to acquiring tuberculous infection[7]. Although the main defect in this patient was impaired B-lymphocyte differentiation and antibody production with normal to mildly elevated levels of T-lymphocytes, the main clinical presentation was of tuberculous meningitis, a devastating complication of Mycobacterium tuberculosis, and patient responded well to anti-tuberculous therapy.

Neurological manifestations in Common Variable Immunodeficiency are rare and literature is not well established. In CVID, infectious complications of nervous system are relatively more common than the inflammatory causes, with an estimated 6-25% prevalence of meningitis. Complications pertaining to autoimmunity are described in 25-30% cases of CVID, with autoimmune cytopenias taking the lead amongst these manifestations[7]. In our case, patient had a negative Coomb's test, no splenomegaly and there was no other clinical or laboratory sign of any autoimmune cytopenia. Establishing the diagnosis of CVID related enteropathy and differentiating it from seronegative Celiac disease was a challenging step in the management of this patient to avoid keeping her on unnecessary gluten-free diet. The Paris consensus published in 2022 for diagnosing enteropathies having villous atrophy with negative celiac serology was adopted for this purpose. According to this, presence of gastrointestinal symptoms in a patient with established diagnosis of CVID, having villous atrophy on duodenal biopsy and exclusion of other causes of atrophic villi including GI infections is necessary while duodenal intraepithelial lymphocytosis is supportive to attribute CVID related enteropathy as the cause of chronic diarrhea in such patients[8]. Moreover, consistent with the findings of our case, this consensus believes that absent plasma cells in GI mucosa, presence of lymphoid hyperplasia and neutrophilic infiltrate on biopsy specimens is not crucial for establishing this diagnosis, hence contradicting the suggestion from Vincenzo et al.[9]

Administration of parenteral immunoglobulins together with the education and counselling of patient and her attendants was adopted as the key management strategy according to the recommended guidelines.[10] Patient was closely observed for any adverse reactions to Intravenous immunoglobulins. Anti-tuberculous therapy was continued for a period of 12 months and patient was called for follow-ups at regular intervals. Her condition improved significantly which highlights the impact of timely diagnosis and treatment of CVID and its associated frequent and rare complications on the physical, mental and social wellbeing of patients.

Conclusion

The diagnosis of Common Variable Immunodeficiency in medical practice is frequently delayed partly due to variability in patient's presentation and also due to lack of resources and awareness in low-resourced countries. The multisystem complications including meningitis, bronchiectasis and enteropathy as described in our case can be prevented by timely diagnosis and adequate management.

Conflict of Interest: None

Funding Source: None

Authors' Contribution

UA: Conception.

SA, MA: Design of the work.

SS, SA, IA: Data acquisition, analysis, or interpretation.

SA, MA, SS, SA: Draft the work.

UA, IS: Review critically for important intellectual content.

All authors approve the version to be published.

All authors agree to be accountable for all aspects of the work.

References

1. Janssen LMA, van der Flier M, de Vries E. Lessons Learned From the Clinical Presentation of Common Variable Immunodeficiency Disorders: A Systematic Review and Meta-Analysis. Front Immunol. 2021; 12:620709.
2. Weifenbach N, Schneckenburger AAC, Lötters S. Global Distribution of Common Variable Immunodeficiency (CVID) in the Light of the UNDP Human Development Index (HDI): A Preliminary Perspective of a Rare Disease. J Immunol Res. 2020; https:// doi.org/10.1155/2020/8416124
3. Cooper CJ, Said S, Quansah R, Khalillullah S, Alozie O. Pneumococcal meningitis in a young adult female with common variable immunodeficiency. Am J Case Rep. 2013; doi: 10.12659/AJCR.889617.

4. Ameratunga R, Woon ST, Gillis D, Koopmans W, Steele R. New diagnostic criteria for common variable immune deficiency (CVID), which may assist with decisions to treat with intravenous or subcutaneous immunoglobulin. Clin Exp Immunol. 2013;174(2):203–11.
5. Tehrani S, Ziaie S, Kashefizadeh A, Fadaei M, Najafi-arab H, Keyvanfar A. Case Report: Pneumonia in a Patient With Combined Variable Immunodeficiency: COVID-19 or Pneumocystis Pneumonia? Front Med. 2022;9(2):1–5.
6. de Martino M, Lodi L, Galli L, Chiappini E. Immune Response to Mycobacterium tuberculosis: A Narrative Review. Front Pediatr. 2019;7(1):464617.
7. Chawla S, Barman P, Tyagi R, Jindal AK, Sharma S, Rawat A, et al. Autoimmune Cytopenias in Common Variable Immunodeficiency Are a Diagnostic and Therapeutic Conundrum: An Update. Front Immunol. 2022; 13(1): 869466.
8. Schiepatti A, Sanders DS, Baiardi P, Caio G, Ciacci C, Kaukinen K, et al. Nomenclature and diagnosis of seronegative coeliac disease and chronic non-coeliac enteropathies in adults: the Paris consensus. Gut. 2022; 71(11):2218–25.
9. Villanacci V, Vanoli A, Leoncini G, Arpa G, Salviato T, Bonetti LR, et al. Celiac disease: Histology-differential diagnosis-complications. A practical approach. Pathologica. 2020;112(3):186–96.
10. Abolhassani H, Sagvand BT, Shokuhfar T, Mirminachi B, Rezaei N, Aghamohammadi A. A review on guidelines for management and treatment of common variable immunodeficiency. Expert Rev Clin Immunol. 2013; 9(6): 561–75.