JPSIM Journal of Pakistan Society of Internal Medicine

Case Report

A Rare Case of Disseminated Histoplasmosis in an Immunocompetent Young Male: Diagnostic Value of Bone Marrow Biopsy and Fungal Morphological Identification

Muhammad Shayan Ashfaq, Natasha Ali

Aga Khan University Karachi, Pakistan

Abstract

The dimorphic fungus Histoplasma capsulatum causes histoplasmosis, an infection that can manifest as anything from a simple, self-limiting illness to a serious, widely spread illness. Fungal culture is still the gold standard for confirmation, but diagnosis is sometimes delayed by its slow development. Bone marrow analysis can offer a quick and accurate diagnostic substitute in these situations. We describe a male immunocompetent patient, age 21, who has had a persistent fever and malaise for three months that have not improved with empirical treatment. Repeated blood cultures and serologic testing came out negative, but laboratory studies showed cytopenias. Grocott-Gomori methenamine silver and periodic acid-Schiff stains, on the other hand, revealed intracellular and extracellular yeast-like organisms in bone marrow aspirate and trephine biopsy that were morphologically consistent with Histoplasma capsulatum.

Keywords: Histoplasma capsulatum, disseminated histoplasmosis, bone marrow biopsy, cytopenia, fungal morphology

How to cite this:

Ashfaq MS, Ali N. A Rare Case of Disseminated Histoplasmosis in an Immunocompetent Young Male: Diagnostic Value of Bone Marrow Biopsy and Fungal Morphological Identification. J Pak Soc Intern Med. 2026;7(2): 160-162

Corresponding Author: Dr. Muhammad Shayan Ashfaq, **Email:** shayanthebest911@gmail.com

Received: 04-11-2025 **Revised:** 14-04-2026 **Accepted:** 04-05-2026 **DOI:** https://doi.org/10.70302/jpsim.v7i2.2632

2709-8729/© 2026 The Author(s). Published by JPSIM on behalf of Pakistan Society of Internal Medicine, Lahore, Pakistan.
This is an open access article under the CC BY 4.0 license https://creativecommons.org/licenses/by/4.0/

Introduction

Histoplasma capsulatum is a systemic fungal disease caused by the dimorphic organism Histoplasma capsulatum. In healthy individuals, it frequently shows no symptoms or only mild signs. Nevertheless, in certain instances, it can result in a serious febrile illness. Among the endemic fungal infections, H. capsulatum is the leading cause of hospitalization, especially in regions where the fungus is commonly found[1]. The infection presents in three main types: acute primary, chronic, and disseminated. Histoplasma capsulatum is distributed globally, with a greater concentration in North and Central America, especially in areas linked to tainted bird or bat feces. The fungus is commonly found in caves, chicken coops, bat habitats, and places with bird nests, where spores are breathed in from the polluted soil or droppings.[2] Environmental factors such as soil composition and moisture play a key role in the proliferation of Histoplasma in these areas.[3]

Histoplasmosis often presents with nebulous symptoms, clinical diagnosis can be challenging. Histopathological analysis, serological testing, and culture are the methods used for diagnosis; bone marrow biopsy is an essential procedure for prompt diagnosis in cases of dissemination.[4]

Although cultural testing is thought to be the most accurate diagnostic technique, its lengthy incubation period may cause treatment to be delayed. Therefore, bone marrow samples must be evaluated histopathologically and cytologically for prompt identification, particularly in patients who present with fever and unexplained cytopenia.[5]

We describe a young, otherwise healthy man from Punjab, Pakistan, who developed widespread histoplasmosis. Exposure to agricultural soil may have been the cause of the infection. This report highlights the importance of bone morrow morphology in the timely diagnosis of this potentially lethal infection.

Case Report

For three months, a 21-year-old male student majoring in agricultural engineering had been experiencing symptoms such as a low-grade fever, vomiting, left-sided upper abdominal pain, fatigue, and weight loss. His past medical history was unremarkable; no recurring infections or issues related to recent travel were known.

Upon physical examination, he showed signs of hepatosplenomegaly and significant cervical lymphadenopathy.

Laboratory tests revealed that the hemoglobin level was 7.8 g/dL, the platelet count was 13×10^9/L, the white blood cell (WBC) count was 4.63× 10^9/L, and the corrected reticulocyte count was 2.9%. After being incubated for six weeks at both 25°C and 37°C, additional diagnostic tests—including a fungal culture— were performed, but the results were negative. Malarial antigens tested using an immunochromatographic kit were negative, and blood cultures showed no growth of organisms. The HIV test returned a non-reactive result. Serological analysis for Brucella abortus and Brucella melitensis antibodies displayed titers of <1:80.

An abdominal ultrasound and other radiological evaluations revealed hepatosplenomegaly, but no apparent cause could be set up. A bone marrow examination was requested due to the patient fever of unknown cause. In addition to reactive lymphocytes, the blood film showed a leucoerythroblastic blood profile.

When the bone marrow aspirate smear was stained with Leishman, numerous round incentive cells with distinctive central clearing were seen (Figure-1). These provocations were set up in clusters, both inside and outdoors histiocytes, with some displaying budding — a typical sign of Histoplasma capsulatum. To further validate the fungal infection, Grocott- Gomori methenamine silver(GMS) and Periodic acid- Schiff(PAS) stains were employed. (Figure-1) Both staining styles returned positive results, with the fungal factors appearing as dark, globular provocations. also, Hematoxylin and eosin staining, Grocott- Gomori methenamine silver (GMS) and Periodic acid- Schiff(PAS) stains of the bone trephine sections showed clusters of Histoplasm capsulatum. (Figure-2)

The observed morphological characteristics — round provocations with central clearing, expiring forms, and their localization within macrophages(histiocytes) — explosively indicated a circulated infection caused by Histoplasma capsulatum. The treating doctor was instantly notified of these findings, and the case was started on intravenous broad- spectrum antifungal treatment.

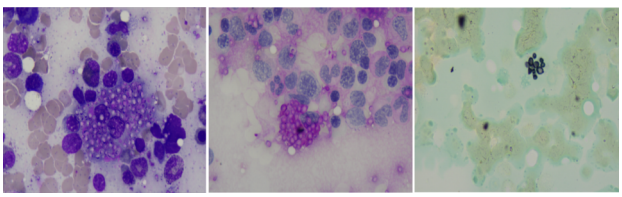

Figure 1: *Bone marrow aspirate showing yeast-like cells of histoplasmosis (Leishman stain, PAS stain and GMS stain; 100x)*

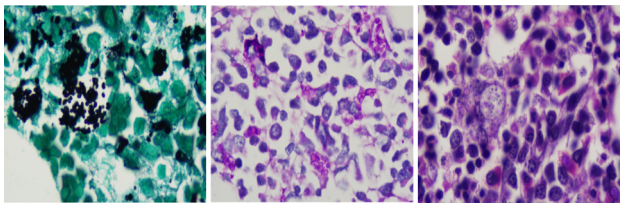

Figure 2: *Bone trephine section showing yeast-like cells of histoplasmosis (Leishman stain, PAS stain and GMS stain; 100x)*

Discussion

Histoplasmosis, which spreads through the air, usually affects individuals with weakened immune systems, such as those with HIV or specific blood cancers.[6] However, in recent times, people with healthy immune systems are also becoming infected, particularly in regions where they are often exposed to the fungus, leading to confusion and irritation.[5] The present case further supports this evidence, showing that even in healthy individuals who have prolonged exposure to the environment, a considerable fungal load and spread can happen. The vague symptoms such as fever, malaise, hepatosplenomegaly, and cytopenias can readily resemble those of other endemic conditions like visceral leishmaniasis or disseminated tuberculosis, which often leads to a delay in diagnosis.[7]

Although culture is still the most common way to diagnose problems, its long incubation period makes it unsuitable for making quick clinical decisions.[8] A vital diagnostic alternative is provided by the histopathological and cytological identification of yeast forms in bone marrow or tissue samples.[5] In this particular case, the culture remained non-contributory, but the morphological identification of characteristic yeast-like organisms during the bone marrow examination facilitated an early diagnosis and prompt initiation of antifungal treatment. The organisms were identified by their small dimensions, narrow-based budding, and perinuclear halo, and were effectively visualized using GMS and PAS staining techniques. These characteristics are essential for differentiating. Histoplasma from other intracellular organisms like Leishmania donovani, which does not exhibit budding and contains a kinetoplast.[5]

Similar results have been seen in previous studies, when bone marrow morphology was primarily used to identify disseminated histoplasmosis in healthy persons, even in cases where cultures were delayed or negative.[5] As prior investigations have emphasized, the detection of yeast forms on bone marrow smears facilitates timely identification and the start of antifungal treatment.[9] A thorough cytomorphologic evaluation of bone marrow is an essential technique for the early detection of disseminated histoplasmosis, particularly in regions with limited access to sophisticated mycological testing,

as demonstrated by the combined results of earlier research and the current case.[10]

The patient's background in agriculture and rural living indicates that exposure to contaminated soil is likely the main source of infection. Similar exposures have been noted in previously reported cases from South Asia, suggesting that there may be unrecognized endemic areas in this region.[11] It is crucial for clinicians and pathologists to enhance their awareness, as misdiagnosing conditions can result in delays or inappropriate treatments. In regions where tuberculosis is common, histoplasmosis might be overlooked because of similarities in clinical and radiological presentations.[7] Incorporating fungal stains routinely into bone marrow evaluations for patients presenting with unexplained fever and cytopenias can enhance diagnostic effectiveness and enable prompt management.[5]

Starting treatment early significantly increases chances of survival, whereas a late diagnosis may lead to fatal results. While comprehensive follow-up data was lacking in this instance, swift identification and communication with the treating physician allowed for immediate therapeutic measures to be taken.[12]

In summary, this situation illustrates that individuals with a healthy immune system working in environments contaminated with fungi can develop disseminated histoplasmosis. When culture and serology tests produce ambiguous findings, a bone marrow biopsy serves as a quick, readily available, and highly effective diagnostic method. Recognizing its cytomorphological characteristics can greatly minimize diagnostic hold-ups and enhance patient outcomes in areas where fungal infections are often overlooked.

Conflict of Interest: None

Funding Source: None

Authors' Contribution

MSA: Conception.

MSA: Design of the work.

NA: Data acquisition, analysis, or interpretation.

NA: Draft the work.

MSA: Review critically for important intellectual content.

All authors approve the version to be published.

All authors agree to be accountable for all aspects of the work.

References

1. Kauffman CA. Histoplasmosis: a clinical and laboratory update. Clin Microbiol Rev. 2007;20(1):115-32.
2. Wheat LJ, Azar MM, Bahr NC, Spec A, Relich RF, Hage C. Histoplasmosis. Infect Dis Clin North Am. 2016;30(1):207-27.
3. de Perio MA, Benedict K, Williams SL, Niemeier-Walsh C, Green BJ, Coffey C, et al. Occupational Histoplasmosis: Epidemiology and Prevention Measures. J Fungi (Basel). 2021;7(7):510.
4. Hage CA, Azar MM, Bahr N, Loyd J, Wheat LJ. Histoplasmosis: Up-to-Date Evidence-Based Approach to Diagnosis and Management. Semin Respir Crit Care Med. 2015;36(5):729-45.
5. Shaikh MS, Majeed Memon A. Disseminated histoplasmosis in an immuno-competent young male: Role of bone marrow examination in rapid diagnosis. Diagn Cytopathol. 2018;46(3):273-6.
6. Adenis AA, Aznar C, Couppié P. Histoplasmosis in HIV-Infected Patients: A Review of New Developments and Remaining Gaps. Curr Trop Med Rep. 2014; 1(2): 119-28.
7. Soeroso NN, Aida A, Pratiwi WB, Utama BSP, Syahruddin E, Sembiring RE. Chronic pulmonary histoplasmosis masquerading as tuberculoma: A case report and literature review. Int J Surg Case Rep. 2025; 133(1): 111555.
8. Azar MM, Hage CA. Laboratory Diagnostics for Histoplasmosis. J Clin Microbiol. 2017;55(6):1612-20.
9. Agarwal P, Capoor MR, Singh M, Gupta A, Chhakchhuak A, Debatta P. An Unusual Presentation of Disseminated Histoplasmosis: Case Report and Review of Pediatric Immunocompetent Patients from India. Mycopathologia. 2015;180(5-6):359-64.
10. Bardia PC, Detroja KN, Maniar RC, Dharsandia HK. A case of disseminated histoplasmosis diagnosed by bone marrow aspiration in immunocompetent patient from nonendemic area, Rajkot, Gujarat. Indian J Pathol Microbiol. 2024;67(1):230-2.
11. Smith DJ, Soebono H, Parajuli N, Grijsen ML, Cavanaugh AM, Chiller T, et al. South-East Asia regional neglected tropical disease framework: improving control of mycetoma, chromoblastomycosis, and sporotrichosis. Lancet Reg Health Southeast Asia. 2025;35:100561.
12. Naji A, Baxter M, Kumi A, Camille Ozaeta J, Onuoha N, Cruz-Vasquez D, et al. A fungal nightmare: A rare and deadly presentation of disseminated histoplasmosis. ID Cases. 2024;38:e02084.