JPSIM Journal of Pakistan Society of Internal Medicine

Case Report

Multicentric Castleman Disease of Hyaline Vascular Type Presenting as Cervical Lymphadenopathy with Systemic Inflammatory Features in a Young Male

Najum Fatima, Arslan Mumtaz

Saleem Memorial Hospital, Lahore, Pakistan

Abstract

Castleman disease is a rare lymphoproliferative disorder with unicentric and multicentric forms. It can mimic tuberculosis, lymphoma, systemic lupus erythematosus and other inflammatory diseases, making diagnosis challenging. Excess interleukin-6 activity is central to many systemic manifestations, particularly in idiopathic multicentric Castleman disease. A 20-year-old male presented with a slowly enlarging left cervical swelling for two years, with rapid progression over three months, evening low-grade fever, night sweats, anorexia and 8-10 kg weight loss. Examination revealed a hard, non-tender left cervical mass. CRP and IL-6 were elevated, while autoimmune, HIV, HHV-8, viral and tuberculosis workup was negative. CT showed a left anterior cervical chain mass with hilar and inguinal lymph node involvement. Excision biopsy demonstrated hyaline vascular Castleman disease morphology. The clinicoradiological and histopathological findings supported multicentric Castleman disease, hyaline vascular type. Because siltuximab was not locally available, the patient was treated with tocilizumab 8 mg/kg intravenously every two weeks, along with tapering corticosteroids. After six doses, he achieved complete remission. This case highlights that Castleman disease should be considered in chronic cervical lymphadenopathy with constitutional symptoms after excluding infection, autoimmune disease and malignancy. Early excision biopsy, systemic staging and targeted anti-IL-6 therapy can lead to excellent clinical response in HHV-8-negative multicentric disease.

Keywords: Castleman disease; multicentric Castleman disease; hyaline vascular type; cervical lymphadenopathy; interleukin-6; tocilizumab.

How to cite this:

Fatima N, Mumtaz A. Multicentric Castleman Disease of Hyaline Vascular Type Presenting as Cervical Lymphadenopathy with Systemic Inflammatory Features in a Young Male: A Case Report. J Pak Soc Intern Med. 2026;7(2): 165-168

Corresponding Author: Dr. Najum Fatima, **Email:** najumfatima@gmail.com

Received: 09-10-2025 **Revised:** 15-04-2026 **Accepted:** 04-05-2026 **DOI:** https://doi.org/10.70302/jpsim.v7i2.2634

2709-8729/© 2026 The Author(s). Published by JPSIM on behalf of Pakistan Society of Internal Medicine, Lahore, Pakistan.
This is an open access article under the CC BY 4.0 license https://creativecommons.org/licenses/by/4.0/

Introduction

Castleman disease (CD), also called angiofollicular lymph node hyperplasia, is a rare non clonal lymphoproliferative disorder characterized by abnormal lymph node hyperplasia and variable systemic inflammation. It was first described as localized mediastinal lymphadenopathy, but later reports have shown involvement of cervical, abdominal, axillary, inguinal and multiple nodal regions.[1,2]

Clinically, CD is classified into unicentric Castleman disease (UCD), involving a single lymph node region, and multicentric Castleman disease (MCD), involving multiple nodal stations. UCD is commonly asymptomatic and curable with excision, while MCD is associated with fever, night sweats, weight loss, hepatosplenomegaly, cytopenias, hypoalbuminemia and raised inflammatory markers.[1-5] Histologically, CD is divided into hyaline vascular, plasma cell and mixed variants. The hyaline vascular pattern shows regressed germinal centers, concentric mantle-zone onion-skinning, vascular proliferation, hyalinized vessels and the classic lollipop follicle appearance. Although hyaline vascular disease is classically unicentric, systemic symptoms may occur when there is multicentric involvement or marked cytokine activation.[2,6] The pathogenesis remains incompletely understood, but dysregulated cytokine activity, particularly interleukin-6 (IL-6), plays an important role in constitutional symptoms and acute-phase responses. Castleman disease can mimic tuberculosis, lymphoma, HIV-related lymphoproliferation, systemic lupus erythematosus, IgG4-related disease and other rheumatological disorders. We report a young male with cervical lymphadenopathy, systemic inflammatory features, raised IL-6

level and biopsy-proven hyaline vascular MCD who responded completely to tocilizumab and corticosteroids after siltuximab could not be obtained locally.[3,8,9]

Case Presentation

A 20-year-old male presented to our department with a swelling on the left side of the neck for two years. The swelling increased in size over the period of 2 years, with more noticeable expansion over the period of last 3 months. The patient also developed fever with evening rise, low grade, intermittent but relieved on taking medication. It was associated with night sweats, anorexia and weight loss of 8-10 kg over a period of 3 months. On clinical examination, a 4.0 × 2.0 cm lump was palpated on the left side of the neck with no tenderness and redness, hard in consistency with smooth surface having regular margins and was adhesive to the surrounding structures. Rest of the systemic examination was unremarkable.

Complete blood count, liver profile, renal profile, urine complete and ESR were all in normal range. C-reactive protein was raised with levels of 50.8 mg/dl (lab range was 0.1-1.0 mg/dl). Serum ferritin level was normal. The immune profile was negative but IL-6 levels were highly raised (70.5 pg/ml, normal range <= 2.0 pg/ml) which showed the presence of systemic inflammation. Serological evaluation for toxoplasma, Epstein-Barr, cytomegalovirus, rubella, HHV-8 and human immunodeficiency virus were negative. IGRA test for tuberculosis was also negative. IgG levels were also normal. Ultrasound neck showed a well-defined heterogeneous lesion measuring 4.2 × 2.2 cm seen in left cervical region. (Figure.1) No lymph node was noted on the right side of neck. Chest x-ray showed opacities in hilar region. CT head and neck, chest, abdomen and pelvic showed a heterogeneous 4.5cm × 2.5 cm × 3cm mass in left anterior cervical chain and enlargement of hilar and inguinal lymph nodes (subcentemetric) which were centrally calcified with abundant peripheral tissue of cystic nature. (Figure.2) FNAC of the cervical swelling was initially performed and showed features of chronic granulomatous disease. However, because of persistent systemic features and radiological suspicion, excision biopsy of the mass in left anterior cervical chain was performed which revealed lymph node exhibiting partly effaced nodal architecture with atretic lymphoid follicles and expanded interfollicular zones. The atretic lymphoid follicles were traversed by vessels forming lollipop follicles. The interfollicular areas showed prominent vascular proliferation with hyalinization of vessel wall. Lymphoid follicle also showed thickened mantle zones with onion skinning. (Figure.3) Immunohistochemical stains CD 20 and CD 3 showed a reactive pattern. CD 30 and CD 15 were negative. There was no evidence of granuloma formation and malignancy. Acid-fast bacilli staining and Ziehl-Neelsen (ZN) staining on the excision biopsy were negative for tuberculosis.

Thus, patient's clinical examination, findings of ultrasound, CT scan, biopsy and immunohistochemical results were suggestive of multicentric Castleman disease-hyaline vascular type. Due to the unavailability of siltuximab, the patient was prescribed tocilizumab at a guideline-supported dose of 8 mg/kg intravenously every two weeks, along with corticosteroids in tapering dose for constitutional features of the disease. Up till now, he has received 6 doses of tocilizumab and the disease is in complete remission.

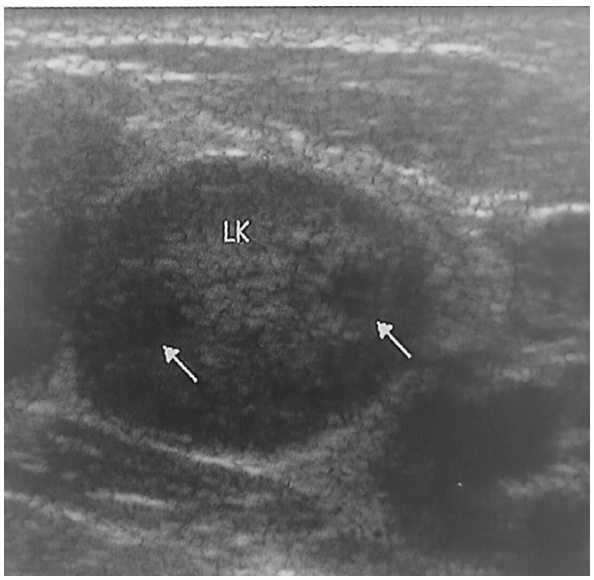

Figure 1. *Ultrasound neck showing a well-defined heterogeneous lesion in the left cervical region.*

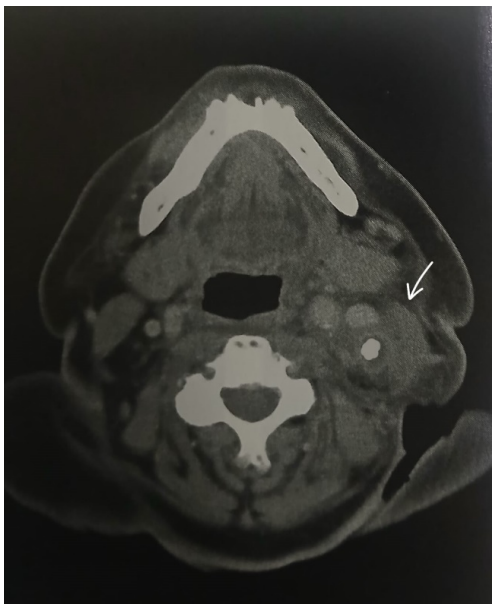

Figure 2: *CT neck showing left anterior cervical chain mass*

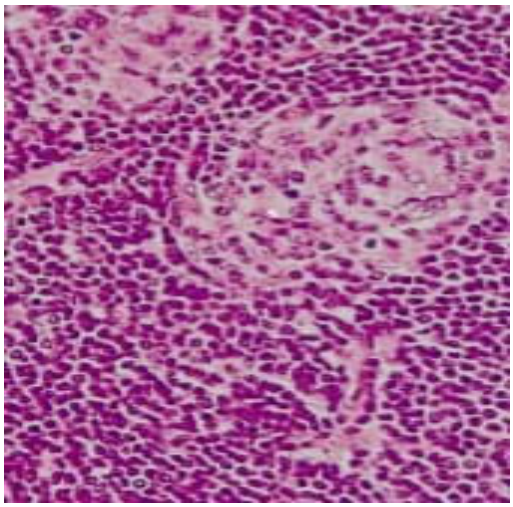

Figure 3: *Lymph node biopsy histology showing hyaline vascular Castleman disease morphology with onion-skinning and lollipop follicles.*

Discussion

This case is important because the patient initially appeared to have a dominant single cervical lymph node mass, but constitutional symptoms and imaging evidence of hilar and inguinal lymph nodes supported a multicentric process. This distinction changes management: UCD is usually treated by complete excision, while MCD requires systemic therapy directed at inflammatory cytokines and B-cell/plasma-cell activation.[5,8]

Cervical CD is well documented but uncommon compared with mediastinal disease. Published cervical cases often present as slowly enlarging neck masses and are diagnosed only after excision biopsy. Many are hyaline vascular UCD and remain well after complete resection. In contrast, our patient had fever, night sweats, anorexia, weight loss, raised CRP and markedly elevated IL-6, which favored systemic inflammatory disease rather than a purely localized mass.[2,6] The differential diagnosis was broad. Tuberculosis was important because of chronic cervical lymphadenopathy, evening fever, night sweats and weight loss, particularly in a high-burden setting. The initial FNAC suggested chronic granulomatous disease, which further strengthened the clinical suspicion of tuberculosis or another granulomatous process. However, FNAC can be misleading in Castleman disease because nodal architecture cannot be adequately assessed. In this patient, negative IGRA, absence of granulomas on excision biopsy and negative acid-fast bacilli staining and negative Ziehl-Neelsen (ZN) staining on the excision biopsy made tuberculosis unlikely. Lymphoma was also a major concern because of B symptoms, but CD15 and CD30 negativity, reactive CD20/CD3 pattern and absence of malignant morphology argued against Hodgkin and non-Hodgkin lymphoma.[5]

Autoimmune disease was considered because MCD can mimic systemic lupus erythematosus and other rheumatological disorders. Reports describe CD presenting with fever, lymphadenopathy, serositis, cytopenias, renal involvement and inflammatory markers resembling SLE. In this patient, immune profile was negative and biopsy supported Castleman disease. This highlights the value of tissue diagnosis when systemic symptoms coexist with persistent lymphadenopathy.[3,4] The excision biopsy was decisive because it contradicted the FNAC impression of chronic granulomatous disease and demonstrated the preserved architectural clues required for Castleman disease. The lymph node showed partly effaced architecture, atretic follicles, expanded interfollicular zones, vascular proliferation, hyalinized vessel walls, mantle-zone onion-skinning and lollipop follicles, characteristic of the hyaline vascular subtype. These features are central to diagnosis, because clinical, radiological and cytological findings alone cannot reliably distinguish Castleman disease from lymphoma, granulomatous disease or metastatic malignancy.[1,7]

Compared with previously published cervical Castleman disease reports, this patient had a more inflammatory phenotype. Many solitary cervical cases show normal inflammatory markers and are managed successfully by excision alone. In contrast, the combination of constitutional symptoms, elevated CRP, high IL-6 and extra-cervical nodal disease in our patient made systemic treatment necessary. This comparison is clinically useful because a prominent accessible node may lead clinicians to assume UCD, while full-body imaging may reveal occult multicentric disease that would otherwise be undertreated.[2,5,6] The negative HIV and HHV-8 results are clinically relevant. HHV-8-associated MCD is more often seen in immunocompromised patients and is frequently managed with rituximab-based therapy. In HHV-8-negative, HIV-negative MCD, the diagnosis is generally idiopathic MCD after exclusion of infections, malignancy, autoimmune disease and POEMS-associated disease.[8,9]

IL-6 is central to the inflammatory biology of iMCD. It stimulates hepatic acute-phase reactants, causes constitutional symptoms and drives systemic inflammation. The marked IL-6 elevation in this patient explained fever, weight loss and raised CRP despite preserved blood counts, albumin, ferritin and immuno-globulin levels. Thus, normal baseline tests do not exclude early or less fulminant MCD when clinical and imaging features are supportive.[9,10] Siltuximab is generally preferred as first-line anti-IL-6 therapy for HHV-8-negative iMCD; however, it was not available locally in this case. Therefore, tocilizumab was selected as an alternative IL-6 receptor inhibitor. International treatment guidance supports tocilizumab 8 mg/kg intravenously every two weeks when siltuximab is unavailable. The patient

received six doses with tapering corticosteroids and achieved complete remission, supporting IL-6 pathway blockade as an effective targeted approach in this setting.[9,10] This case highlights three practical lessons. First, CD should be considered in chronic lymphadenopathy with systemic inflammation after common mimics are excluded. Second, excision biopsy with immunohistochemistry remains essential, especially when FNAC suggests granulomatous disease but the overall clinicoradiological picture remains atypical. Third, staging with cross-sectional imaging is necessary before labeling disease as unicentric, because a dominant cervical node may obscure multicentric involvement.[1,8]

Conclusion

Castleman disease is a rare but important cause of chronic lymphadenopathy and systemic inflammation. This case describes a young male with progressive cervical lymphadenopathy, constitutional symptoms, elevated CRP and IL-6, negative infectious and autoimmune workup, and histopathological features of hyaline vascular Castleman disease. Although initial FNAC suggested chronic granulomatous disease, excision biopsy established the correct diagnosis. Additional hilar and inguinal lymph node involvement supported multicentric disease. Complete remission with tocilizumab, chosen because siltuximab was unavailable, supports the role of IL-6 pathway blockade in HHV-8-negative multicentric Castleman disease.

Conflict of Interest: None

Funding Source: None

Authors' Contribution

NF: Conception.

NF: Design of the work.

AM: Data acquisition, analysis, or interpretation.

AM: Draft the work.

NF: Review critically for important intellectual content.

All authors approve the version to be published.

All authors agree to be accountable for all aspects of the work.

References

1. Sikora M, Dąbrowska-Leonik N, Buda P, Wolska-Kuśnierz B, Jahnz-Różyk K, Pac M, et al. Castleman Disease—Still More Questions than Answers: A Case Report and Review of the Literature. J Clin Med. 2025; 14(8):2799.
2. Iyer S, Bhatti MI, Halliday M. Castleman's disease — A case report. Int J Surg Case Rep. 2010; 1(3): 25–26.
3. Wang L, Chen H, Shi J, Tang H, Li H, Zheng W, et al. Castleman disease mimicking systemic lupus erythematosus: A case report. Medicine (Baltimore). 2018; 97(38):e12291.
4. Hu W, Kong Y, Hu B, Ai J, Zhang P. Atypical clinical presentation associated with Castleman disease: a case report and review of the literature. Front Med. 2025; 12:e1626722.
5. Izuchukwu IS, Tourbaf K, Mahoney MC. An unusual presentation of Castleman's disease: a case report. BMC Infect Dis. 2003; 3:20.
6. Saadallah MAH. Castleman's disease: A rare case report and review of literature. Int J Surg Case Rep. 2022; 95: 107282.
7. Eward WC, DeWitt SB, Brigman BE, Kontogeorgakos V, Lagoo AS. Extranodal Castleman disease of the extremities: a case report and review of the literature. Skeletal Radiol. 2014; 43(6):1627–31.
8. Fajgenbaum DC, Uldrick TS, Bagg A, Frank D, Wu D, Srkalovic G, et al. International, evidence-based consensus diagnostic criteria for HHV-8-negative/idiopathic multicentric Castleman disease. Blood. 2017; 129(12):1646–57.
9. Van Rhee F, Voorhees P, Dispenzieri A, Fosså A, Srkalovic G, Ide M, et al. International, evidence-based consensus treatment guidelines for idiopathic multicentric Castleman disease. Blood. 2018; 132(20): 2115 – 24.
10. Lang E, van Rhee F. Idiopathic multicentric Castleman disease: An update in diagnosis and treatment advances. Blood Rev. 2024; 64:e101161.