JPSIM Journal of Pakistan Society of Internal Medicine

Case Report

Ancient Beyond Its Years: Giant Intrathoracic Ancient Schwannoma in an Adolescent

Maha Batool, Minahil Binte Irfan, Imman Akram, Farah Babar, Muhammad Imran

Department of Medicine, Gulab Devi Teaching Hospital, Lahore

Abstract

Posterior mediastinal masses in the paediatric population present a diagnostic challenge because the imaging appearances of diverse entities frequently overlap. Neurogenic tumours are among the most common primary neoplasms of the posterior mediastinum, constituting roughly 20% of cases in adults and up to 35% in children. Schwannomas, well-encapsulated tumours arising from the myelin-forming cells of peripheral nerves, represent the commonest benign subtype within this group. The ancient schwannoma is an uncommon variant characterised by protracted degenerative change — cystic transformation, intralesional haemorrhage, vessel wall hyalinisation, dystrophic calcification, and nuclear pleomorphism — that accumulates over years. Despite the alarming histological appearances, ancient schwannoma carries no malignant potential; however, its atypical radiological and microscopic features may prompt an erroneous presumptive diagnosis.

We report a 15-year-old girl who presented with a one-year history of progressive exertional dyspnoea and nocturnal dry cough. Contrast-enhanced CT of the chest revealed a large hypodense septated lesion in the right thoracic apex displacing the superior mediastinal vasculature, an appearance that suggested a bronchogenic cyst. She underwent right posterolateral thoracotomy, and a complete en bloc excision of a 7.3 cm encapsulated mass was performed. Histopathological examination confirmed an ancient schwannoma. The postoperative recovery was uncomplicated. This report illustrates the diagnostic pitfalls of an ancient schwannoma in a young patient and affirms the central role of tissue pathology in the evaluation of atypical mediastinal masses.

Keywords: Schwannoma, mediastinal masses, exertional dyspnea, well-encapsulated tumours

How to cite this:

Batool M, Irfan MB, Akram I, Babar F, Imran M. Ancient Beyond Its Years: Giant Intrathoracic Ancient Schwannoma in an Adolescent. J Pak Soc Intern Med. 2026;7(3): 262-266

Corresponding Author: Dr. Maha Batool **Email:** mahabatool16@gmail.com

Received: 23-01-2026 **Revised:** 19-05-2026 **Accepted:** 12-08-2026 **DOI:** https://doi.org/10.70302/jpsim.v7i3.2649

2709-8729/© 2026 The Author(s). Published by JPSIM on behalf of Pakistan Society of Internal Medicine, Lahore, Pakistan.
This is an open access article under the CC BY 4.0 license https://creativecommons.org/licenses/by/4.0/

Introduction

Mediastinal masses represent a heterogeneous group of lesions whose accurate characterisation requires systematic synthesis of clinical, radiological, and pathological information.[1] Neurogenic tumours are among the most prevalent primary mediastinal neoplasms: they account for approximately 20% of cases in adults and up to 35% in children, and they arise almost exclusively in the posterior mediastinum from neural crest-derived elements, including peripheral nerves and the sympathetic ganglia.[2] Schwannoma, also termed neurilemmoma, is the most frequently encountered benign peripheral nerve sheath tumour. It is composed entirely of Schwann cells, grows slowly within a well-defined fibrous capsule, and characteristically remains solitary and non-infiltrative.[3]

Ancient schwannoma is a histological variant in which the classical schwannoma architecture is overlaid by advanced degenerative change that accumulates over years, including cystic degeneration, intralesional haemorrhage, hyalinisation and thickening of vessel walls, dystrophic calcification, and conspicuous nuclear atypia with pleomorphism. Crucially, these features carry no prognostic weight and should not be construed as evidence of malignant transformation.[4,5] Nevertheless, the combination of atypical nuclei and heterogeneous or cystic radiological appearances can closely mimic a malignant neoplasm, a congenital developmental cyst, or an infectious process, making accurate preoperative characterisation particularly difficult.[6,7]

Most intrathoracic schwannomas originate from intercostal nerves or the thoracic sympathetic chain and manifest as posterior mediastinal masses, predominantly in adults aged 40 to 60 years.[8] Occurrence in adolescents is well recognised but uncommon, and ancient-type degeneration in this age group has been described only in isolated reports.[9] Tumours at the thoracic apex may impinge on adjacent vascular structures and compress the ipsilateral lung, generating symptoms that can mislead the clinician toward a primary cardiorespiratory diagnosis.

Presently a 15-year-old girl in whom a large right apical thoracic mass was interpreted on imaging as a bronchogenic cyst. The definitive diagnosis of ancient schwannoma was established only after histopathological examination of the surgical specimen. This report highlights the diagnostic pitfalls inherent to ancient schwannoma in young patients and underscores the indispensable contribution of tissue examination in the workup of mediastinal lesions with atypical features.

Case Presentation

A 15-year-old female presented to the outpatient department of Gulab Devi Hospital, Lahore, on April 9, 2026, reporting progressive breathlessness on exertion and a persistent nocturnal dry cough of one year's duration. The dyspnoea had begun insidiously and worsened over time, attaining Grade II severity on the Modified Medical Research Council (mMRC) scale; it was consistently aggravated by deep inspiration and was accompanied by orthopnoea, though paroxysmal nocturnal dyspnoea was not reported. The cough was non-productive, predominantly nocturnal, and sufficiently severe to disrupt sleep; antitussive agents provided only partial and temporary relief. She denied fever, wheeze, chest pain, haemoptysis, weight loss, or prior respiratory infections. No developmental or congenital abnormalities were documented, and vaccination records were unavailable.

Examination revealed a thin adolescent in no acute distress. Assessment of the right upper hemithorax demonstrated reduced chest wall excursion, diminished tactile vocal fremitus, and dullness to percussion restricted to the right upper zone; the remainder of the chest was resonant. Auscultation over the affected region revealed vesicular breath sounds with markedly reduced air entry; vocal resonance was paradoxically increased in the same zone. The trachea was midline. Taken together, these signs were consistent with a right apical space-occupying lesion exerting a compressive effect on the underlying lung.

Routine haematological and biochemical investigations were within normal limits, and viral serology was negative. A posteroanterior chest radiograph demonstrated a well-defined homogeneous opacity in the right upper zone consistent with an underlying mass lesion (Figure 1). Contrast-enhanced CT of the chest revealed a well-circumscribed, rounded, hypodense lesion measuring 6.2 x 6.5 x 7.3 cm in the right apical region, abutting the superior mediastinum. The lesion did not enhance following contrast administration, exhibited internal attenuation of 25-35 Hounsfield Units, and contained fine septations. It displaced the superior vena cava, both brachiocephalic (innominate) veins, and the azygos vein without evidence of vascular invasion. The radiological impression favoured a bronchogenic cyst, with a hydatid cyst considered a less probable alternative (Figure 2).

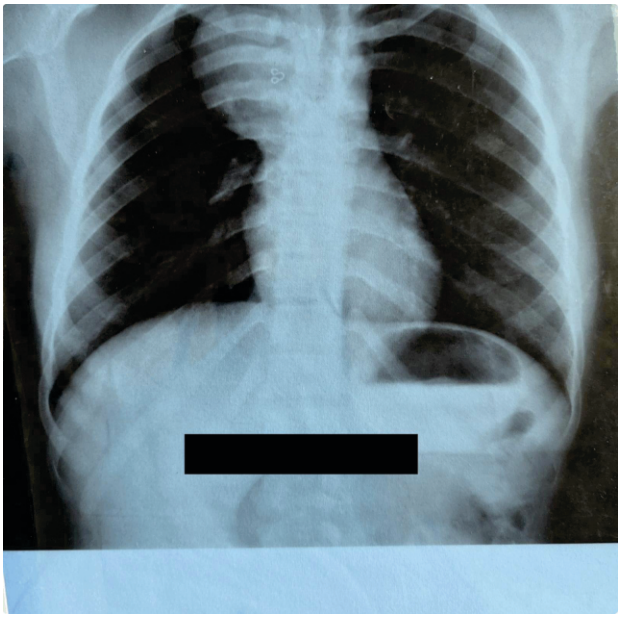

Figure 1: *Chest radiograph.*

[Demonstrating a well-defined, homogeneous opacity in the right upper lung zone, suggestive of an underlying pulmonary mass.]

On account of the lesion's size, its compressive relationship with major mediastinal vessels, and the diagnostic uncertainty, elective surgical excision was planned. On April 16, 2026, the patient underwent right posterolateral thoracotomy under general anaesthesia with single-lung ventilation, entering the pleural cavity through the fifth intercostal space. Intraoperatively, a well-encapsulated semi-solid mass was identified occupying the right thoracic apex and compressing the upper lobe of the ipsilateral lung. The tumour maintained close contact with the

superior vena cava, brachiocephalic veins, and azygos vein, which were markedly displaced but not invaded. The lesion appeared to originate from an intercostal nerve at the apex. Meticulous dissection from all adherent structures was performed, and complete en bloc resection of the mass with its intact capsule was accomplished without injury to adjacent neurovascular elements. Haemostasis was secured, and two intercostal chest drains were inserted before layered thoracotomy closure (Figure 3).

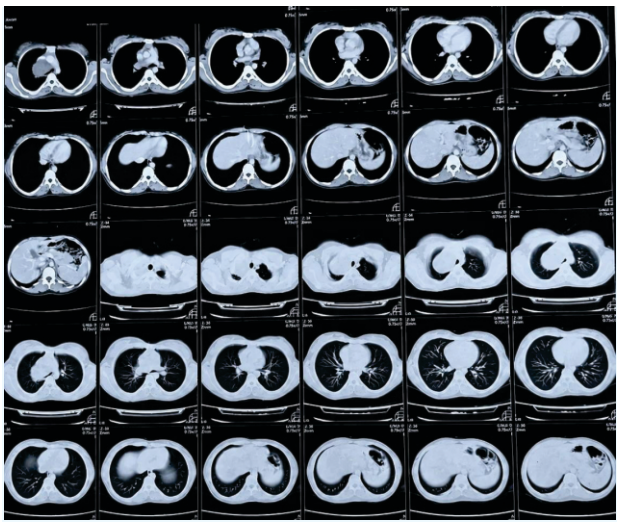

Figure 2: *Contrast-enhanced CT chest .*

[Showing a well-defined, non-enhancing hypodense cystic lesion in the right apical region adjacent to the superior mediastinum, causing mass effect on the superior vena cava and adjacent mediastinal vessels, suggestive of a bronchogenic cyst.]

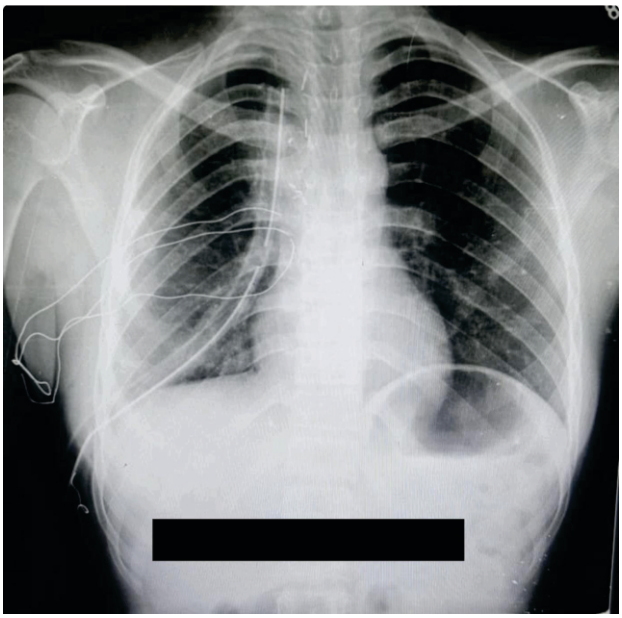

Figure 3: *Intraoperative photograph.*

[showing a well-encapsulated right apical thoracic mass compressing adjacent mediastinal structures, including the superior vena cava and major venous tributaries, before complete surgical excision.]

Gross pathological examination of the specimen showed a well-circumscribed, encapsulated mass with a smooth, intact external surface, measuring 7.3 cm in greatest dimension. Cut sections were predominantly solid with focal cystic areas and degenerative change; no macroscopic haemorrhage or necrosis was identified. The specimen was submitted in its entirety for histopathological assessment (Figure 4).

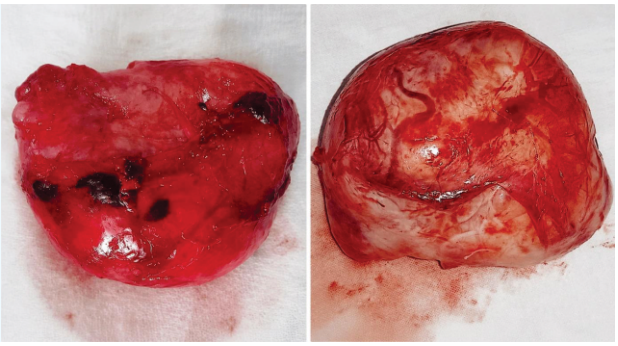

Figure 4: *Gross examination revealed a well-circumscribed, encapsulated mass measuring 7.3 cm in its greatest dimension.*

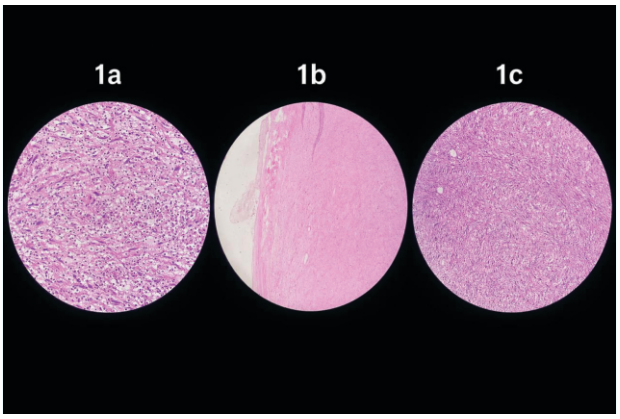

Figure 5: *Histopathological examination.*

[showing a benign spindle cell neoplasm with alternating Antoni A and Antoni B areas, Schwann cell morphology, and marked degenerative changes, including nuclear atypia, multinucleated giant cells, hyalinized vessels, hemorrhage, and myxoid degeneration, consistent with ancient schwannoma (H&E stain).]

Histopathological examination revealed a benign spindle cell neoplasm composed of alternating hypercellular (Antoni A) and hypocellular myxoid (Antoni B) zones. Tumour cells displayed elongated, wavy nuclei consistent with Schwann cell differentiation. Extensive degenerative change was

evident throughout: nuclear pleomorphism, scattered multinucleated giant cells, thick-walled hyalinised blood vessels, focal haemorrhage, and myxoid stromal change. Notably, mitotic figures were absent, and no necrosis was identified. These histomorphological appearances were diagnostic of ancient schwannoma (Figure 5).

The postoperative course was uneventful. The patient remained haemodynamically stable throughout her hospital stay, and her clinical progress was satisfactory. Intercostal drains were removed on the fifth postoperative day following confirmation of adequate lung re-expansion and minimal drainage output. She was discharged in stable condition on April 20, 2026.

Discussion

Ancient schwannoma is an uncommon histological variant in which the classical biphasic schwannoma architecture becomes increasingly obscured by degenerative changes — cystic transformation, haemorrhage, hyalinisation, calcification, and nuclear pleomorphism — that accumulate over a protracted course.[6,7] Most reported cases have involved adults in the fourth to sixth decades of life; the entity is considerably rarer in adolescents, rendering the present case clinically unusual both by virtue of the patient's age and the tumour's dimensions at the time of diagnosis.

The majority of intrathoracic schwannomas arise from intercostal nerves or the thoracic sympathetic chain and present as posterior mediastinal masses.[8] Apical location is less common and may result in compressive symptoms referable to the lung or mediastinal vasculature, as observed in our patient, where displacement of the superior vena cava and brachiocephalic veins was the likely substrate for her progressive dyspnoea.

The preoperative radiological assessment in this case was misleading. The CT appearances of a large non-enhancing hypodense lesion with fine septations and no identifiable solid component are characteristic of a bronchogenic cyst rather than a neurogenic tumour.[10,11] Ancient schwannomas frequently generate this imaging phenotype because cystic degeneration transforms what would otherwise appear as a heterogeneous solid posterior mediastinal mass. The consequent diagnostic uncertainty — encompassing congenital cysts, hydatid disease, lymphatic malformations, and cystic mediastinal teratomas — reinforces the fundamental importance of histopathological examination in achieving a definitive diagnosis.

Microscopically, the diagnostic hallmarks of ancient schwannoma are the alternating Antoni A and B areas, Schwann cell morphology, and the constellation of degenerative features — hyalinised vessels, myxoid stroma, haemorrhage, and nuclear pleomorphism — in the context of absent or negligible mitotic activity and no necrosis.[12,13] Recognition of this pattern is essential to avoid misclassifying the tumour as a malignant spindle cell neoplasm based on nuclear atypia alone; the absence of mitoses and necrosis is the critical discriminating observation.

Complete surgical excision is simultaneously diagnostic and curative. The intimate relationship of the tumour with the superior vena cava and major mediastinal veins in the present case precluded a minimally invasive approach; open thoracotomy afforded the exposure necessary for safe dissection and en bloc resection with an intact capsule. The patient's uncomplicated recovery and early discharge are consistent with the excellent outcomes reported following complete resection in the literature. No adjuvant therapy is indicated for this pathologically benign entity.

Conclusion:

Ancient schwannoma, though rarely encountered in adolescence, should be included in the differential diagnosis of cystic or heterogeneous apical and posterior mediastinal masses regardless of patient age. Its imaging characteristics frequently overlap with those of bronchogenic cysts and other congenital mediastinal lesions, making preoperative tissue diagnosis unreliable in the majority of cases. Histopathological examination of the surgical specimen remains the cornerstone of accurate diagnosis. Complete surgical excision is curative and associated with an excellent prognosis; early recognition prevents unnecessary therapeutic delay or misguided intervention.

Ethical Approval: The IRB/EC approved this study via letter no.

Conflict of Interest: None

Funding Source: None

Authors' Contribution

MB: Conception.

MBI, IA: Design of the work.

FB, MI: Data acquisition, analysis, or interpretation.

MBI, IA, FB: Draft the work.

MB, MI: Review critically for important intellectual content.

All authors approve the version to be published.

All authors agree to be accountable for all aspects of the work.

References

1. Mura R, Pochepnia S, Kifjak D, Khenkina N, Prosch H. A diagnostic approach to mediastinal masses in clinical practice. BJR Open. 2025;7(1):tzaf009.
2. Carter BW, Benveniste MF, Madan R, de Groot PM, Truong MT, Marom EM. Primary mediastinal tumours. Part II: Tumours of the middle and posterior mediastinum. Radiographics. 2017;37(2):413-36.
3. den Bakker MA, Weissferdt A. Neurogenic tumours of the posterior mediastinum and differential diagnosis considerations. Histopathology. 2024;84(1):238-52.
4. Ahuja S, Khan AA, Zaheer S. Intrapulmonary ancient schwannoma: a rare tumour. Indian J Surg Oncol. 2024;15(1):193-6.
5. Bhatia N, Dey P, Kumar Y, Singh G. Retroperitoneal ancient schwannoma: case presentation. ResearchGate. [Accessed 2026 May 25]. Available from: [https://www.researchgate.net.]
6. Venkataramana CG, Gupta S, Nayak R, Km S, Rai S, Rao R. Comprehensive study of ancient schwannoma: exploring histomorphological diversity and diagnostic challenges. Rare Tumors. 2024;doi:10.1177/20363613241274259.
7. Weerakkody Y, Gaillard F, Iqbal S. Ancient schwannoma. Radiopaedia.org. [Accessed 2026 May 25]. [Available from: https://radiopaedia.org.]
8. Miyawaki M, Karashima T, Abe M, Takumi Y, Hashimoto T, Kamohara R, et al. Giant benign intrathoracic schwannoma: a decade-long progression towards fatality. J Cardiothorac Surg. 2023;18(1):328.
9. Korbet SM, Whittier WL. Management of adult minimal change disease. Clin J Am Soc Nephrol. 2019;14(6):911-3.
10. Aydogdu K, Findik G, Kaya S, Koksal D, Demirag F. Schwannoma arising in a bronchogenic cyst wall. Asian Cardiovasc Thorac Ann. 2015;23(3):328-31.
11. Zahra K, Khalid A, Ali T, Omair M, Afshan G, Khursheed S. Posterior mediastinal ancient schwannoma mimicking a cyst. Int J Pathol. 2018;16:122-125.
12. Abdellatif E, Kamel D, Mantilla JG. Schwannoma. PathologyOutlines.com. [Accessed 2026 May 25]. Available from: [https://www.pathologyoutlines.-com.]
13. Shilpa B. Ancient schwannoma: a rare case. Ethiop J Health Sci. 2012;22(3):215-8.