JPSIM Journal of Pakistan Society of Internal Medicine

Case Report

Unmasking Sturge-Weber Syndrome: A Challenging Case of Refractory Seizures, Facial Angiomas, and Glaucoma in a Young Patient

Saeed Ur Rehman, Ahsen Shah, Majid Rashid , Kamran Saeed , Saad Ali

Department of Internal Medicine, Khyber Teaching Hospital, Peshawar.

Abstract

Sturge-Weber Syndrome (SWS) is a rare congenital neurocutaneous disorder associated with a port-wine stain, leptomeningeal angioma, and glaucoma. Here, we present a case of a 16-year-old boy with classical SWS who had a history of seizures since 6 months of age, intellectual disability, and glaucoma. Imaging revealed prominent leptomeningeal enhancement affecting the right temporal and occipital. The patient received intravenous anti-epileptic medication, antibiotics, and regular follow-up was scheduled. Early detection and treatment are critical to prevent ophthalmic and cerebral complications. The management of SWS requires a multidisciplinary approach.

Keywords: Sturge-Weber Syndrome, Refractory Seizures, Facial Angiomas, Glaucoma

How to cite this:

Rehman SU, Shah A, Rashid M, Saeed K, Ali S. Unmasking Sturge-Weber Syndrome: A Challenging Case of Refractory Seizures, Facial Angiomas, and Glaucoma in a Young Patient. J Pak Soc Intern Med. 2025;6(2): 194-196

Corresponding Author: Dr. Majid Rashid **Email:** kmciteadventurers@gmail.com

Received: 08.10.2024 **Revised:** 10-12-2024 **Accepted:** 08-05-2025

DOI: https://doi.org/10.70302/jpsim.v6i2.2537

2709-8729/© 2025 The Author(s). Published by JPSIM on behalf of Pakistan Society of Internal Medicine, Lahore, Pakistan.
This is an open access article under the CC BY 4.0 license https://creativecommons.org/licenses/by/4.0/

Introduction

Sturge-Weber Syndrome(SWS) also known as encephalotrigeminal angiomatosis is a rare congenital disorder. It is one of the neurocutaneous syndromes associated with distinctive facial port-wine stain, leptomeningeal angioma, and glaucoma. Its incidence is 1 per 20,000-50,000 live births.[1] The disorder is caused by sporadically occurring somatic activating mutation in the GNAQ gene on chromosome 9 involved in signal transmission.[2] Clinically, SWS presents with a congenital birthmark on the face, seizures, intellectual disability, and eye abnormalities. Here, we present a case of classical SWS.

Case Report

A 16-year-old boy presented in emergency department with status epilepticus and fever. After initial measures, he was admitted to ICU for further management. The patient received various medications to control seizures and was later shifted to the medical ward. According to his father, the boy has a history of seizures from the age of 6 months which have progressively worsened since then. Despite taking multiple anti-epileptic drugs in the past, the patient continues to experience seizures once or twice a day. According to his mother, he was developmentally delayed and was unable to talk. His history is significant for glaucoma for which he underwent bilateral trabeculectomy at the age of 5 years. He later lost vision in his left eye. There is no family history of epilepsy.

Examination showed multiple, well-defined, red to purple colored patches involving the face along the distribution of trigeminal nerve bilaterally, extending into the scalp. The left half of the body was predominantly affected. These stains were present at birth. The patient exhibited marked facial deformity secondary to soft tissue and bone hypertrophy, primarily in the maxillary region. Intraoral examination revealed gingival hypertrophy, dental malocclusion, and decreased number of teeth in the upper jaw. Other than poor dental hygiene, there was relative sparing of the lower jaw. The patient had decreased visual acuity in the right eye (6/60) and no vision on the left side. There were no focal neurological deficits, and gait was normal.

Figure 1: *A. Facial port-wine stain and deformity due to soft tissue swelling. B, C. port-wine stains on front and back. D. gingival hypertrophy*

Imaging: CT scan showed dense gyriform calcifications affecting the right occipital and temporal lobes. Previously, an MRI with gadolinium enhancement demonstrated prominent leptomeningeal enhancement affecting the right temporal and occipital lobes. Surprisingly, the left cerebral hemisphere was unremarkable.

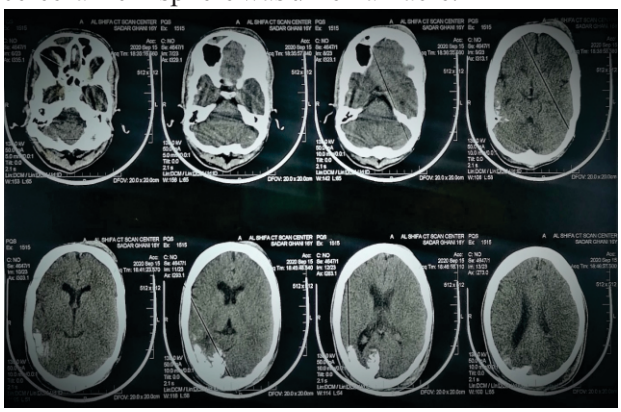

Figure 2: *CT scan showing cortical and subcortical calcifications involving right temporal and occipitoparietal regions.*

Management: The patient received intravenous anti-epileptic medication to control his seizures, as well as appropriate antibiotics. Parents were counseled regarding the potential triggers for seizures and the importance of annual ophthalmic examinations. A neurosurgical consultation was scheduled to consider surgical treatment of the patient's refractory seizures. Patient was referred to an ophthalmologist and a dermatologist. A regular follow-up was scheduled and the patient was discharged on oral medications including low-dose aspirin and dose-adjusted anti-epileptics.

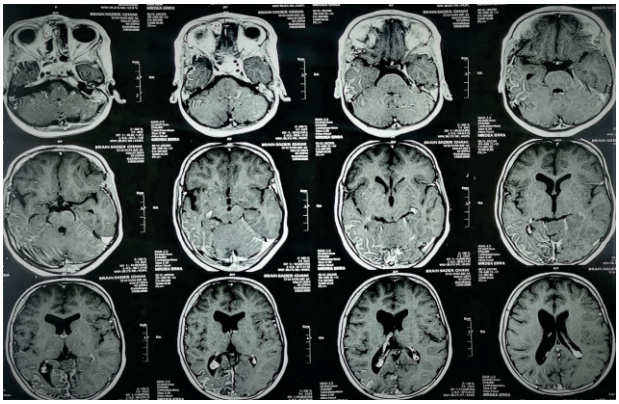

Figure 3: *MRI with contrast demonstrating leptomeningeal enhancement in right temporal and occipital regions.*

Discussion

Sturge-Weber Syndrome is a multisystem disorder with ocular, cutaneous neurological, and ocular manifestations. The most characteristic finding is a port wine stain on the face which follows the course of ophthalmic division of trigeminal nerve mostly.[1] Sturge Weber Syndrome or encephalotrigeminal angiomatosis is the part of the groups of disorders called phakomatoses. An abnormal development of the primordial vasculature bed occurs during the early stages of cerebral vascularization in Sturge Weber Syndrome. Because of this aberrant development the overlying meninges are highly vascularized and the brain underneath these vessel become atrophic and develop calcification, mainly involving the molecular layer of the cerebral cortex.[2]

The clinical manifestation of the Sturge Weber Syndrome depends on the involvement of various system and may vary extensively, it includes leptomeningeal angiomas, various ocular signs, ipsilateral gyriform calcification, hemiparstehsia, hemiplegia, and seizures.[3] The prevalence of Sturge Weber Syndrome is 1:50 000 live births.[4] Sturge-Weber Syndrome is said to be complete when both facial and CNS involvement is present. If one area is affected than sturge Weber is said to be incomplete. The Roach scale[5] is employed for the following classification: Type I: Leptomeningeal and facial angiomas; glaucoma may be present; Type II: Just facial angiomas; glaucoma may be present; Type III: Isolated leptomeningeal angiomas; glaucoma is typically absent.

Additional differential diagnoses comprise angio-osteodystrophy syndrome, Rendu-Oslar-Weber syndrome, Maffuci's syndrome, Von Hippel Lindau disease, and Klippel Trenaumy-Weber syndrome.[6,7]

Eye examination and contrast MRI should be performed in suspected individuals for early diagnosis.[8] The management of SWS requires a multidisciplinary approach that includes a dermatologist, neurologist, and an ophthalmologist. Treatment depends on the involved system, degree of involvement, and severity of clinical features. Supportive treatment is given to mitigate the clinical severity caused by each symptoms. Early treatment of seizures is important to prevent progression of neurological damage.[9] Anti-epileptic drugs should be initiated early and continued for life. Low-dose aspirin has been shown to reduce frequency of cerebrovascular events and seizures in these patients.[10] For those with refractory seizures, surgery is indicated either through hemispherectomy or corpus callosotomy.[11] Intraocular pressure monitoring allows early detection of glaucoma and initiation of therapy to prevent optic nerve damage. Some patients may require surgery such as goniotomy or trabeculectomy.[9]

In our case, anti-epileptic were started to control the fits. The presence of stain can cause a great deal of psychological distress for family and patients and therefore can cause greater effect on the personality of the patient. Dermabrasion, flash lamp pulsed dye laser, and tattooing are all effective ways to improve port wine stains.

Conflict of Interest: *None*

Funding Source: *None*

Authors' Contribution:

SUR, MR: Conception

AS, KS: Design of the work

KS, SA: Data acquisition, analysis, or interpretation

AS, KS, SA: Draft the work

SUR, MR: Review critically for important intellectual content

All authors approve the version to be published

All authors agree to be accountable for all aspects of the work

References

1. Gill NC, Bhaskar N. Sturge-Weber Syndrome: A case report. Contemp Clin Dent. 2010;1(3):183-5.
2. Tripathi AK, Kumar V, Dwivedi R, Saimbi CS. Sturge-Weber Syndrome: oral and extra-oral manifestations. BMJ Case Rep. 2015; doi:10.1136/bcr-2014-207663.
3. Garro SJ, Bradshaw WT. Sturge-Weber Syndrome: a case study. Adv Neonatal Care. 2014;14(2):96-102.
4. Welty LD. Sturge-Weber Syndrome: A case study. Neonatal Netw. 2006;25(2):89-98.
5. Roach ES. Neurocutaneous syndromes. Pediatr Clin North Am. 1992;39:591-620.
6. Suprabha B, Baliga S. Total oral rehabilitation in a patient with port wine stains. J Indian Soc Pedod Prev Dent. 2005;23(2):99-102.
7. Mukhopadhyay S. Sturge-Weber Syndrome: A Case report. J Indian Soc Pedod Prev Dent. 2008;26(5):29-31.
8. Waelchli R, Aylett SE, Robinson K, Chong WK, Martinez AE, Kinsler VA. New vascular classification of port-wine stains: improving prediction of Sturge-Weberrisk. Br J Dermatol. 2014;171(4):861-7.
9. Higueros E, Roe E, Granell E, Baselga E. Sturge-Weber Syndrome: A Review. Actas Dermosifiliogr. 2017;108(5):407-17.
10. Bay MJ, Kossoff EH, Lehmann CU, Zabel TA, Comi AM. Survey of aspirin use in Sturge-Weber Syndrome. J Child Neurol. 2011;26(6):692-702.
11. Comi A. Current Therapeutic Options in Sturge-Weber Syndrome. Semin Pediatr Neurol. 2015;22(4):295-301.