

## Case Report

## Cerebral Venous Sinus Thrombosis in Pregnant Woman Presenting with Hemiplegia and Aphasia

Sami Ullah Mumtaz, Somia Iqtadar, Zafar Niaz, Mohsin Masud, Ali Asad Khan, Sajid Abaidullah

*Department of Medicine, King Edward Medical University / Mayo Hospital Lahore.*

### How to cite this:

Mumtaz SU, Iqtadar S, Niaz Z, Masud M, Khan AA, Abaidullah S. Cerebral venous sinus thrombosis in pregnant woman presenting with hemiplegia and aphasia. *J Pak Soc Intern Med.* 2021;2(2): 148-150

**Corresponding Author:** Dr. Sami Ullah Mumtaz.

**Email:** drsumumtaz@gmail.com

### Introduction

Cerebral venous sinus thrombosis (CVT) is an uncommon non-septic condition that may lead to death if left untreated. Its common predisposing factors are pregnancy, puerperium, oral contraceptive pills & hypercoagulable states.<sup>1-3</sup> It can affect any age group & is responsible for up to 5% for all cerebrovascular accidents.<sup>4</sup>

CVT incidence has been described by different researchers in their studies. It has been described as 9% by Towbin in 1973, while Daif described 7 out of 100,000 patients in 1995.<sup>5,6</sup> CVT has diverse clinical features & decreased mortality & morbidity because of the recent advancements in treatment.<sup>4</sup> CVT is found more in females as compared to males.<sup>7</sup>

Clinical features of CVT are divided into 2 main categories, on the basis of brain involvement:

First impaired venous drainage leads to raised intracranial pressure that causes headache, blurring of vision & vomiting. Secondly venous insult results in brain damage that causes focal neurological signs & fits. Both these features may be present from the start or anytime during the course of the disease.<sup>8</sup>

With the advancements in neuroradiology it is now easier to diagnose CVT. Computed Tomography of brain (CT) is the initial modality in all the patients who come with the brain symptoms such as fits, vomiting, blurring of vision, headache & altered sensorium.<sup>9</sup> Magnetic Resonance Imaging (MRI) is the investigation of choice for diagnosing CVT with Magnetic Resonance Venography (MRV) for exact localization of thrombus in the venous sinus.<sup>9</sup>

### Case Description

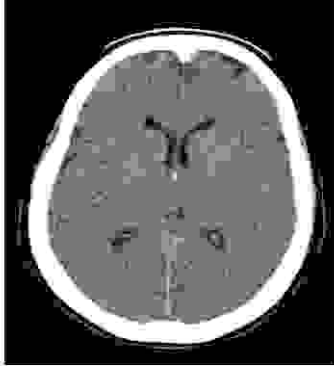**Clinical Situation:** A 23-year old, pregnant lady, gravida 2 para 1, at 28 weeks of gestation, presented

in Mayo Hospital Lahore, Pakistan, medical emergency department with sudden onset altered state of consciousness for past 2 days and weakness of right half of the body for 1 day.


**Course of Events:** She presented with sudden onset altered state of consciousness for past 2 days and weakness of right half of the body for 1 day after having emergency lower segment caesarian section (LSCS) for intrauterine death due to eclampsia. There was no preceding history of any brain trauma, polyuria, polydipsia, polyphagia, jaundice, abdominal distention, hematemesis, melana, haematuria, pyuria & frothy urine. There was no history of poisoning or any drug intake. Weakness was sudden in onset, complete without diurnal variation and had a static course. She had no such history in her first pregnancy and family history was also insignificant. She also developed headache at presentation along with aphasia and an attack of generalized tonic clonic fit lasting for around 5 minutes.

On examination she was of normal height and built with pulse rate 88/min, blood pressure of 150/100 mmHg, temperature 98.6 degree Fahrenheit, respiratory rate 18/min and had pallor and palmer erythema. Her neurological examination showed an aphasic lady having Glasgow Coma Scale of 10/15 (E: 4 M: 5 V: 1) & impaired higher mental functions. She had hypertonia & hyperreflexia in right upper & lower limbs Power was 0/5 in right both upper and lower limbs & planters were upgoing on right side. Her Neurological examination of left upper & lower limbs was normal. Her right eye vision was also impaired (CN-II). Sensations of touch pain and temperature were intact on left half of face however impaired on right half of face (CN-V). Her sensations of touch, pain, temperature and vibration were reduced in

whole right half of the body as compared to left side. Her abdominal, cardiovascular & respiratory systems examination was normal.



**Fig 1:** CT Brain Plain Showing Brain Edema



**Fig 2:** MRV Showing Thrombosis Of Left Transverse Sinus

**Clinical Work up & Resolution:** Her laboratory findings showed microcytic hypochromic anemia with Hb of 8.9mg/dl, White blood cell count 10,500/mm<sup>3</sup> hematocrit 30%; platelets 160,000/mm<sup>3</sup>; bilirubin 1.2mg/dl, alanine transaminase 60 U/L; aspartate transaminase 75U/L; lactate dehydrogenase 340 U/L, urea 49meq/L, creatinine 1.3meq/L and spot urine sample showed 3+ proteinuria. Initial plain CT brain, showed cerebral edema without any ischemic or haemorrhagic area. Considering patient age & history & CT brain finding, Magnetic Resonance Venography (MRV) was performed that showed left transverse cerebral venous sinus thrombosis with area of infarction. A repeat CT brain plain after 24hrs also confirmed infarct as well. The patient was admitted & monitored in the intensive care unit & was treated conservatively with IV heparin and mannitol, Antihypertensive & anticonvulsants. She remained admitted in the hospital for 29 days, & responded well to the treatment. Patient was improved & was discharged at GCS 15/15.

### Discussion

Our patient was an unusual case of CVT presenting as cerebrovascular accident in her third trimester. Cere-

bral venous sinus thrombosis (CVT) is an uncommon condition which presents as a result of hypercoagulability & venous stasis during pregnancy & puerperium. The venous stasis as a result of prolonged bed rest, changes in the coagulation system, blood loss during instrumental delivery or Caesarean section along with dehydration lead to thrombosis.<sup>10</sup> This results in cytotoxic and vasogenic edema, and ultimately infarction.<sup>11</sup> Thrombosis is more common in larger sinuses like superior sagittal sinus as compared to transverse sinus. Usual presenting complaint is headache.<sup>12</sup> Other symptoms may be generalized or focal tonic clonic seizures, vertigo, dizziness, hemiparesis, aphasia & sensory loss.<sup>11</sup> Most important diagnostic test is Magnetic Resonance Imaging (MRI) and Magnetic Resonance Venography (MRV) of brain. Other hypercoagulable states, vacuities, multiple sclerosis, CNS tumors & infections, postpartum cerebral angiopathy, subarachnoid haemorrhage (SAH) & arterial strokes are the important differential diagnoses.<sup>13,14</sup> In our case, first CT was done due to neurological features & later MRV & repeat CT brain confirmed the diagnosis.

In the acute treatment of CVT, anticoagulation is drug of choice. It has significantly reduced mortality and morbidity.<sup>15</sup> Mortality ranges between 2.5% to 20%. Our case had complete recovery & was discharged.<sup>16</sup>

At the end, it is emphasized that CVT should be considered a differential diagnosis when patient presents with neurological symptoms during pregnancy. The patient should be thoroughly evaluated and anticoagulation should be started without any delay if diagnosis is confirmed.

### Conclusion

CVT is a rare condition along with coincident postpartum Cerebrovascular accident. This case emphasizes the significance of carefully evaluating hemiplegia & aphasia in the postpartum period. CVT should always be considered in the differential diagnosis. An MRI combined with MRV is best choice for the investigation of a suspected CVT in a pregnant woman. Mortality & morbidity can be avoided by early start of anticoagulation.

### Consent

Written informed consent was obtained from the patient for publication of this case report and accompanying images.

### Conflict of Interest

None

### Funding Source

None

## References

1. Buccino G, Scoditti U, Patteri I, Bertolino C, Mancia D. Neurological and cognitive long term outcome in patients with cerebral venous sinus thrombosis. *Acta Neurologica Scandinavica*. 2003;107(5):330-5.
2. Patel MR, Robertson HJ, Coombs BD, Salamon GM, Krasny RM, Smirniotopoulos JG. Brain, venous sinus thrombosis. [Updated, 2003; cited 2021]; Available from:[[www.emedicine.com/radio/topic105.htm](http://www.emedicine.com/radio/topic105.htm)].
3. Soleau SW, Schmidt R, Stevens S, Osborn A, MacDonald JD. Extensive experience with dural sinus thrombosis. *Neurosurgery*. 2003;52(3):534-44.
4. Bousser M-G, Ferro JM. Cerebral venous thrombosis: an update. *Lancet Neurol*. 2007;6(2):162-70.
5. Towbin A. The syndrome of latent cerebral venous thrombosis: its frequency and relation to age and congestive heart failure. *Stroke*. 1973;4(3):419-30.
6. Daif A, Awada A, Al-Rajeh S, Abduljabbar M, Al Tahan AR, Obeid T, et al. Cerebral venous thrombosis in adults: A study of 40 cases from Saudi Arabia. *Stroke*. 1995;26(7):1193-5.
7. Ameri A, Bousser M. Cerebral venous thrombosis. *Neurologic Clinics*. 1992;10(1):87-111.
8. Saposnik G, Barinagarrementeria F, Brown RD, Bushnell CD, Cucchiara B, Cushman M, et al. Diagnosis and management of cerebral venous thrombosis: a statement for healthcare professionals from the American Heart Association/American Stroke Association. *Stroke*. 2011;42(4):1158-92.
9. Justich E, Lammer J, Fritsch G, Beitzke A, Walter G. CT diagnosis of thrombosis of dural sinuses in childhood. *EuJRadiol*. 1984;4(4):294-5.
10. Bousser M-G, Russell RR. *Cerebral venous thrombosis*. W B Saunders publishers. London. 1st edition 1997: pp 47-87.
11. Stam J. Thrombosis of cerebral veins and sinuses. *N Engl Med J*. 2005;352(17):1791-8.
12. Ameri A, Bousser MG. Cerebral venous thrombosis. *Neurologic Clin*. 1992;10(1):87-111.
13. Einhaupl KM, Villringer A, Meister W, Meister W, Mehraein S, Garner C, et al. Heparin in sinus venous thrombosis. *Lancet*. 1991;338 (8767):597-600.
14. de Bruijn SFTM, Stam J, for cerebral venous sinus thrombosis study group. Randomized, placebo controlled trial of anticoagulant treatment with low molecular weight heparin for cerebral venous thrombosis. *Stroke*. 1999;30 (3):384-8.
15. Agostoni E, Aliprandi A, Longoni M. Cerebral venous thrombosis. *Expert Rev Neurotherapeut*. 2009; 9(4):553-64.
16. Fink JN, McAuley DL. Cerebral venous sinus thrombosis: a diagnostic challenge. *Intern Med J*. 2001;31(7):384-90.