

## Case Report

## A Rare Case of Non Obstructive Hypertrophic Cardiomyopathy in a Young Female

Syeda Kisa Fatima Zaidi, Aziz ur Rehman, Kausar Mir Janan, Munazza Jamshed

*Arif Memorial Teaching Hospital*

### Abstract

We hereby report a rare case of non-obstructive cardiomyopathy in a young female with features of heart failure. Her previous diagnosis was made of restrictive cardiomyopathy but the interventricular septal thickness was increased which suggested hypertrophic cardiomyopathy. Patient was reevaluated with a fresh echocardiography after which the diagnosis was confirmed and she was started on medication to control the symptoms of heart failure. Patient was asked to come for regular follow up and was advised to avoid competitive sports and related activities.

### How to cite this:

Zaidi SKF, Rehman AU, Janan KM, Jamshed M. A Rare Case of Non Obstructive Hypertrophy Cardiomyopathy in a Young Female. *J Pak Soc Intern Med.* 2021;2(2): 154-156

**Corresponding Author:** Dr.Syeda Kisa Fatima Zaidi .

**Email:** kisazaidi23@icloud.com

### Introduction

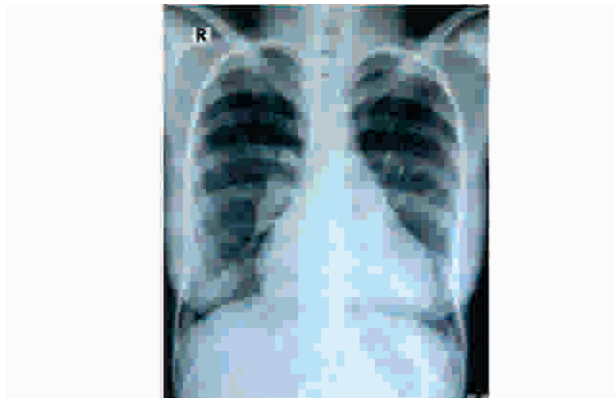
Hypertrophic cardiomyopathy, previously known as Idiopathic Hypertrophic Subaortic Stenosis<sup>1</sup> is a genetic disorder characterized by left ventricular hypertrophy unexplained by secondary causes, and a non-dilated left ventricle which may be seen with preserved or increased ejection fraction. It is more commonly asymmetric with the most severe hypertrophy involving the basal interventricular septum at times causing obstruction to the left ventricular outflow.<sup>2</sup>

For the past 20 years, the occurrence of HCM was found at about 1 in 500<sup>3</sup>. It is estimated that HCM gene carriers could be as high as 1:200<sup>4</sup>. It was found that in Pakistan hypertrophic cardiomyopathy was the second most common form of cardiomyopathy after DCM. Most of the diagnosed patients had the mean age of 5 + 5.9 years.<sup>5</sup>

Patient presentation is phenotypically varied, ranging from asymptomatic to heart failure or sudden cardiac death. The overall rate of disease-related complications such as sudden death, end-stage heart failure and fatal stroke is approximately 1-2%, but risk in individual patients varies according to their age, disease severity and the underlying cause of the hypertrophy.<sup>6</sup> The etiology of the disease is mainly based on various patterns of inheritance including autosomal dominant, recessive, X-linked and maternal or it could be related to various metabolic syndromes. It was estimated that 60% of adults with moderate to severe hypertrophy have autosomal dominantly inherited mutations in one of 10 genes that encode proteins of the cardiac sarcomere.<sup>7</sup>

The mainstay of diagnosis is by echocardiography and electrocardiography where as in some patients cardiac MRI may be required. Any pattern of left ventricular hypertrophy is consistent with the diagnosis but the majority has asymmetrical septal hypertrophy with or without left ventricular outflow obstruction. In first-degree family members of patients with unequivocal disease, ventricular wall thickness of more than 13 mm is sufficient for diagnosis.

Here we report an interesting case of a young female who was being treated for heart failure due to restrictive cardiomyopathy. Reevaluation of her investigations led to a confirmed diagnosis of non-obstructive hypertrophic cardiomyopathy.



## Case Report

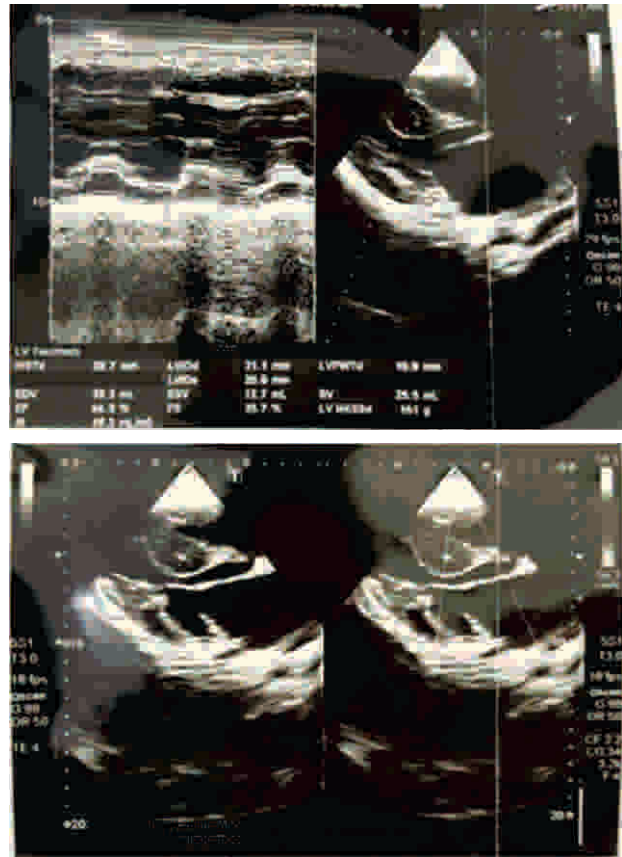
A 20 year old female presented with complaints of abdominal bloating, orthopnea and paroxysmal nocturnal dyspnea for 6 months which worsened in last 2 weeks. Patient also complained of on and off fever and SOB on exertion.

Symptoms started approximately 8 years ago when she started having SOB on exertion with frequent fever and sore throat. Hb was found to be low for which she was often given I/V iron infusions. Within 1 year patient started having dizziness and falls after climbing stairs. Later gradually developed abdominal distension, SOB worsened with orthopnea and PND. CT scan of the abdomen done in 2014 only showed incidental cardiomegaly which led the patient to visit a cardiologist. Echo performed at that time showed thickened cardiac muscles according to the patient. Cardiac MRI was advised which showed dilated IVC, a non-dilated left ventricle with normal radial systolic function but reduced long axis function. All other findings were normal. Patient was started on spiroside but continued to have abdominal fullness and shortness of breath due to ascites and pleural effusions for which furosemide and b blocker were also added. Echocardiography done in December, 2019 showed only left ventricle hypertrophy with normal systolic function and grade II-III diastolic dysfunction. Right ventricle was dilated with fair systolic function. EF was 60%. Cardiologist performing the echo suggested restrictive cardiomyopathy but there was increased interventricular septal thickness which urged us to believe a different diagnosis. Ultrasound abdomen showed enlarged congested liver, right sided pleural effusion and Dilated IVC. CT abdomen findings were consistent with liver parenchymal changes suggesting cardiac cirrhosis. LFTs were within normal range except mildly deranged bilirubin.

On general physical examination, patient had pallor and mildly pitting pedal edema. JVP was raised 3 cm above sternal angle. Chest was clear. Cardiovascular examination yielded a well sustained apex beat in 5th ICS. Heart sounds were normal, no murmurs were auscultated except a loud P2. On abdominal examination liver was found to be palpable 1 finger breadth below costal margin, smooth in texture. There was no shifting dullness seen.

A fresh echo was advised to be performed by experienced hands which suggested non obstructive hypertrophic cardiomyopathy with interventricular septum of 20 mm (n: <10) small sized LV cavity with EF of 65%. Grade 1 diastolic dysfunction. Markedly increased LA volume index, moderately enlarged RA, full sized RV with depressed global systolic function. IVC was dilated just like previous reports.

Patient was prescribed verapamil, spiroside, pentoxifylline along with a multivitamin and was advised to avoid strenuous exercise and related activities.



## Discussion

Patients with hypertrophic cardiomyopathy are at risk for developing serious complications like diastolic ventricular dysfunction, obstruction to left ventricular outflow, imbalance between myocardial oxygen supply and demand, and cardiac arrhythmias hence it is important to timely diagnose the condition. A number of patients remain asymptomatic and die of sudden cardiac arrest in young adulthood. Diagnosis in such a case can only be made at autopsy<sup>8</sup>. It is therefore important to do family screening so relatives who are at risk can be identified.<sup>9</sup>

Echocardiography is the mainstay for the diagnosis of this condition which is subjected to human error if not done by experienced hands. Patients with high clinical suspicion of cardiac structural abnormality must be evaluated in detail through echocardiography and cardiac MRI.<sup>5,10</sup> Unfortunately, in Pakistan we do not have many available centers providing this facility which can lead to delay in the definitive diagnosis.

The goal of medical therapies in HCM is symptom reduction, with no clear role in asymptomatic patients. Pharmacotherapies in HCM are largely directed at reducing LVOT obstruction and avoidance of medic-

ations that increase LVOT obstruction like vasodilators and digitalis. Patients with symptomatic HCM mainly present with features of heart failure. The treatment guidelines focus on prescribing a diuretic along with a b blocker. Patients should be advised to avoid strenuous activities and competitive sports especially those with obstructive cardiomyopathy.<sup>10</sup> Control of conventional risk factors such as sedentary lifestyle, hypertension, dyslipidemia, and diabetes require regular clinical follow-ups to timely identify progression of the disease if necessary.<sup>11</sup>

Invasive options are also available which are aimed at reducing the interventricular septal thickness such as septal myectomy and alcohol septal ablation (ASA). Dual chamber pacemaker with optimized atrioventricular delay can be of help to reduce LVOT obstruction in some HCM patients.<sup>6</sup>

Prognosis and life expectancy in such cases depend on the severity of the illness and myocardial structural features therefore risk stratification must be done. LVOT obstruction can be much more debilitating than non-obstructive HCM.

#### Conflict of Interest

None

#### Funding Source

None

#### References

- Braunwald e, Lambrew CT, Rockoff SD, Ross J jr, Morrow AG. Idiopathic hypertrophic subaortic stenosis. I. A description of the disease based upon an analysis of 64 patients. *Circulation*. 1964 Nov;30:SUPPL 4:3-119. doi:10.1161/01.cir.29.5s4.iv-3. PMID: 14227306
- Wolf CM. Hypertrophic cardiomyopathy: genetics and clinical perspectives. *Cardiovasc Diagn Ther*. 2019 Oct;9(Suppl 2):S388-S415. doi: 10.21037/cdt.2019.02.01. PMID: 31737545; PMCID: PMC6837941.
- Semsarian C, Ingles J, Maron MS, Maron BJ. New perspectives on the prevalence of hypertrophic cardiomyopathy. *J Am Coll Cardiol*. 2015 Mar 31; 65(12): 1249-1254. doi: 10.1016/j.jacc.2015.01.019. PMID: 25814232.
- Baudhuin, Linnea & Kotzer, Katrina & Kluge, Michelle & Maleszewski, Joseph. (2015). What Is the True Prevalence of Hypertrophic Cardiomyopathy?. *Journal of the American College of Cardiology*. 66. 1845-1846. 10.1016/j.jacc.2015.07.074.
- Ilyas S, Fawad A, Ilyas H, Hameed A, Awan ZA, Zehra A, Ilyas M, Fazli A. Echomorphology of cardiomyopathy: review of 217 cases from 1999 to 2010. *J Pak Med Assoc*. 2013 Apr;63(4):454-8. PMID: 23905440.
- Geske JB, Ommen SR, Gersh BJ. Hypertrophic Cardiomyopathy: Clinical Update. *JACC Heart Fail*. 2018 May;6(5):364-375. doi: 10.1016/j.jchf.2018.02.010. Epub 2018 Apr 11. PMID: 29655825.
- Elliott P, McKenna WJ. Hypertrophic cardiomyopathy. *Lancet*. 2004 Jun 5;363(9424):1881-91. doi:10.1016/S0140-6736(04)16358-7. PMID: 15183628.
- Marian AJ, Braunwald E. Hypertrophic Cardiomyopathy: Genetics, Pathogenesis, Clinical Manifestations, Diagnosis, and Therapy. *Circ Res*. 2017 Sep 15; 121(7):749-770. doi: 10.1161/CIRCRESAHA.117.311059. PMID: 28912181; PMCID: PMC5654557.
- Lafreniere-Roula M, Bolkier Y, Zahavich L, Mathew J, George K, Wilson J, Stephenson EA, Benson LN, Manlihot C, Mital S. Family screening for hypertrophic cardiomyopathy: Is it time to change practice guidelines? *Eur Heart J*. 2019 Dec 1;40(45):3672-3681. doi:10.1093/eurheartj/ehz396. PMID: 31170284; PMCID: PMC6885133.
- Ommen SR, Mital S, Burke MA, Day SM, Deswal A, Elliott P, Evanovich LL, Hung J, Joglar JA, Kantor P, Kimmelstiel C, Kittleson M, Link MS, Maron MS, Martinez MW, Miyake CY, Schaff HV, Semsarian C, Sorajja P. 2020 AHA/ACC Guideline for the Diagnosis and Treatment of Patients With Hypertrophic Cardiomyopathy: A Report of the American College of Cardiology/American Heart Association Joint Committee on Clinical Practice Guidelines. *Circulation*. 2020 Dec 22;142(25):e558-e631. doi: 10.1161/CIR.0000000000000937. Epub 2020 Nov 20. Erratum in: *Circulation*. 2020 Dec 22;142(25):e633. PMID: 33215931.
- Wolf CM. Hypertrophic cardiomyopathy: genetics and clinical perspectives. *Cardiovasc Diagn Ther*. 2019 Oct;9(Suppl 2):S388-S415. doi: 10.21037/cdt.2019.02.01. PMID: 31737545; PMCID: PMC6837941.