

Original Article

Immunoreactivity of Thyroid Transcription Factor-1 for Diagnosis of Primary Breast Carcinoma

Amber Hassan^{1*}, Imrana Tanvir², Riffat Mehboob¹, Syed Amir Gilani¹, Fridoon Jawad Ahmad^{3,4}, Muhammad Akram Tariq³, Gibran Ali³, Shehla J Akram⁵ and Javed Akram³

Faculty of Allied Health Sciences, The University of Lahore, Lahore, Pakistan, ² Pathology Department, King Abdul Aziz University, Rabigh, Saudi Arabia, ³ Department of Physiology, University of Health Sciences, Lahore, Pakistan, ⁴ Institute of Regenerative Medicine, University of Health Sciences, Lahore, Pakistan, ⁵ Akram Medical Complex, Lahore, Pakistan.

Abstract

Objective: To determine the Immunolocalization of thyroid transcription factor-1 (TTF-1) in primary breast carcinomas.

Methods: The cross-sectional study was conducted at University of Lahore, Lahore. A total of 110 cases of primary breast carcinomas were included. TTF-1 immunohistochemistry was performed. However, the frequency with which TTF-1 expression is observed in breast carcinomas is unknown. To address this, we carried out Immunohistochemical staining for TTF-1 on primary breast carcinomas submitted for routine estrogen receptor, progesterone receptor, and HER2 testing.

Results: A total of 110 cases were selected for this study according to our inclusion criteria. There were 105 female patients (95.45%) and 5 male patients (4.55%). A total of 6 (5.45%) cases were positive for TTF-1 as compared to 104 (94.5%) negative cases. The data was stratified according to age and gender. Chi-square test was applied with significant results kept at $p=0.05$. There was no significant association between TTF-1 expression in males and females and different age groups ($P=0.143$ for gender and $p=0.223$ for age groups).

Conclusions: Expression varied from focal and weak to diffuse and strong and was seen in both invasive and in situ components. We conclude that a small proportion of breast carcinomas show TTF-1 expression. Therefore, the presence of TTF-1 immunoreactivity in a carcinoma cannot by itself be used to exclude the possibility of a breast origin

Keywords: Thyroid transcription factor, Immunohistochemical stain, Breast carcinomas.

How to cite this:

Hassan A, Tanvir I, Mehboob R, Gilani SA, Ahmad FJ, Muhammad Akram Tariq MA, et.al., Immunoreactivity of Thyroid Transcription Factor-1 for Diagnosis of Primary Breast Carcinoma. J Pak Soc Intern Med. 2020;1(1):28-34.

Corresponding Author: Prof. Javed Akram **Email:** vc@uhs.edu.pk/jakramaimc@gmail.com

Introduction

Breast cancer (BC) represents the most common malignancy in females. Approximately 1.7 million new BC cases and 521,900 breast cancer related deaths were reported globally in 2012, most of which are adenocarcinomas.¹ In Pakistan, BC accounts for 46.7% and 49.5% of all malignancies in females according to different

large scale studies.² BC rate in Pakistan is among the highest in Asia and is 2.5 times higher as compared to the neighboring countries.² In a similar note survival of BC patients is much higher in developed countries as compared to less developed countries of the world due to improved screening, more accurate diagnoses and availability of newer treatment. In contrast, many

of the patients of BC in Pakistan present at late stages in which the treatment and sometimes the diagnosis too becomes more difficult. This delayed presentation may be attributed to cultural barriers, less awareness and poor socioeconomic status and unavailability of health resources.⁴ Late diagnosis and biological factors lead to increased stage and grade of tumors at presentation, in Pakistani population.⁵ Breast cancer has been documented to metastasize to various sites in human body, including but not limited to lungs, liver, bone and brain. Many of the breast primary tumors show de-novo metastatic disease at the time of initial diagnosis, these figures reaching as high as 25% in Asian populations.⁶ Histologic grade of a tumor refers to its differentiation. Histologic grade is considered as one of the important prognostic factors in BC and high grade tumors have been documented to have an aggressive clinical course.⁷ Most tumors show at least a vague resemblance to their site of origin, especially in a low grade tumor. Some tumors also have specific features which can be appreciated wherever they are located. For example, melanin pigment presence points towards diagnosis of a melanoma, papillary configurations with specific nuclear characteristics point toward a papillary carcinoma. A high grade BC is poorly differentiated with little resemblance, if any, to its normal counterpart.⁸ Therefore, histological identification especially on the routine Hematoxylin and Eosin stains is difficult and special stains, like Immunohistochemical markers, need to be used to correctly diagnose them. Poorly differentiated morphology also leads to early metastasis to distant sites and worse prognosis. Histological features in most high grade tumors are similar to each other irrespective of their site of origin and therefore it is difficult to confidently diagnose them and distinguish from malignancies from other sites.⁹ Even in tumors of lower grade, it is difficult to distinguish between a primary and a secondary adenocarcinoma because of similar histo-

pathology features. Most of the metastases in lung are due to adenocarcinomas, not unlike adenocarcinomas of its own. Primary adenocarcinomas of lung have multiple subtypes, each having its own separate morphologic spectrum which may cause confusion with adenocarcinomas arising from other sites.⁹ Therefore, histology of a tumor is sometimes not sufficient to reach a conclusive diagnosis and additional measures need to be performed. Occult metastases are sometimes found with lung and other malignancies. "Cancers of unknown primary site" are also encountered routinely in clinical practice and represent 3 to 5% of cancers.¹⁰

Various radiological modalities have proved helpful in diagnosis and management of these cases. Accuracy in staging of cancers has improved by using these techniques. Radiological features can also guide towards subtyping of cancers and detection of site of origin or a metastatic cancer. Ultrasound has been conventionally used for early detection of cancers, as an adjunct to other diagnostic measures. Newer modalities, like Computed tomography (CT) and Positron Emission Tomography (PET) are now being routinely used for diagnostic as well as therapeutic help.^{11,12}

Correct identification of malignant tumors becomes very complicated in metastatic tumors, especially of those from unknown primary site. This problem is compounded in cases where this metastatic deposit is incidentally found during investigations for a lung pathology and it becomes a mystery to determine whether it is originating from the same area or got here as a secondary deposit from elsewhere. This determination has important clinical and therapeutic implications.¹³ The standard clinical and radiologic measures cannot be very helpful in determining the site of origin in all of these cases and pathologists are required to point towards the right direction by incorporating Immunohistochemical and molecular diagnostic measures.¹⁴ Correct diagnosis is essential for correct treatment.

It has been assumed that expression of TTF-1 in a carcinoma excludes the possibility of a breast origin and that its expression may be particularly useful in helping to distinguish between

carcinomas of breast and lung origin in problematic cases.^{5,16} TTF-1, alternatively known as NKX2-1 (NK2 homeobox 1),^{18,19} is a tissue specific homeodomain containing 38-kDa transcription factor protein with DNA binding activity, which is mapped to chromosome 14q13.317.²⁰ It is known to play a dual role in development of lung cancer by having oncogenic as well as tumor suppressive functions. TTF-1 Immunohistochemical stain is normally expressed by thyroid and lung epithelial showing a nuclear staining pattern, and it has been considered a useful immunohistochemical marker for staining tumors arising from thyroid (e.g. follicular and medullary cancers) and lung cancers, particularly lung adenocarcinomas.²¹ However, recent studies²² described TTF-1 expression in a rare cases of neuroendocrine carcinoma of the breast. In addition, few studies had demonstrated that invasive breast carcinoma (confirmed by clinical findings and other immunophenotypic features) showed unequivocal expression of TTF-1. However, the frequency with which TTF-1 expression is observed in breast carcinomas is unknown. The purpose of this study, therefore, was to evaluate the prevalence of TTF-1 expression in an unselected series of breast carcinomas. Correct diagnosis is essential for determining disease course, prognosis and treatment of a case. With this research, we may be able to help the patients in getting appropriate treatment suitable for their type of cancer.

Materials and Methods

The Study was conducted at Faculty of Allied Health Sciences, The University of Lahore, Lahore, Pakistan. A total of 110 formalin fixed paraffin embedded (FFPE) blocks of BC were included. Medical and personal history of patients consisted of age, span of disease, tumor site/size, progression of disease, staging/grading etc. Age range was 25-65 years. For collection of data, we followed American Joint Committee for cancer staging and End results reporting. All the parameters of Declaration of Helsinki were respected in this study. Classification of tumor was based on WHO criteria such as Well differentiated, moderately differentiated and

poorly differentiated breast carcinoma for grade I, grade II and grade III respectively. All the slides were routinely stained with Hematoxylin-Eosin to assess the morphology of cells and proper classification of cases.

ER, PR, HER2 and Ki-67staining:

Immunohistochemistry (IHC) for PR, ER, HER2/neu and Ki-67 was accomplished on FFPE tissue segments as part of the routine clinical assessment of these cases using anti-ER antibody (DAKO, Denmark), anti-ER antibody (DAKO, Denmark), anti-HER2 (1:400 to 1:600, DAKO, Denmark), anti-PR antibody (DAKO, Denmark) with Visualize system for detection. Lobular and ductal normal areas of breast were as control for ER, PR and HER2 IHC whereas appendix tissue was set as control for Ki-67. Olympus (Model U-DO3) was used for microscopy.

Immunohistochemistry (IHC) for TTF-1:

FFPE sections of 4µm were deparaffinized with xylene and decreasing grades of alcohol, washed in distilled water and then Phosphate Buffer Saline (PBS). These sections were pretreated with citrate buffer in microwave and were allowed to cool for at least 20 minutes. Washings in distilled water and PBS was done before 3% H₂O₂ (30 minutes) to block the endogenous peroxidase activity. TTF1 antibody clone SPT24, Leica/ Novacastar, 1:400 dilutions was applied to the sections for 45-50 minutes in humid chamber. Washing step in PBS was done for 10-15 min. Slides were then incubated with secondary antibody Horse Raddish Peroxidase (HRP) for 45-50 minutes and washed again with PBS (10-15 minutes). 3,3'-Diaminobenzidine (DAB) is applied for 5-10 minutes and counter stained with hematoxyline for 2 minutes. FFPE sections were dipped in increasing grades of alcohol and then xylene for 5 minutes each. DPX mounting medium was used and slides were cover slipped. Methods are similar to one of our previous study on oral squamous cell carcinoma.²²

Grading of IHC:

Cell counting at 10 and 40X was done for the evaluation of protein expression and counts were made as in our previous study.²³ Scoring for ER, PR, HER2 and Ki-67 was done by ALLRED method proposed by Qureshi and Pervez.²⁴ Cases were considered TTF-1 positive if they showed any nuclear staining for this marker. TTF-1

positive cases were evaluated for intensity of expression (weak or strong) and expression pattern (focal or diffuse). TTF-1 expression was classified as focal if nuclear immunoreactivity for TTF-1 was seen in less than 50% of the tumor cells and as diffuse if immunoreactivity was seen in 50% or more of the tumor cells. The bias of inter observer variation was minimized by showing all cases to one consultant with a minimum experience of 5 years. Confounding variables was minimized by strictly adhering to inclusion and exclusion criteria. The collected information was entered in the statistical package for social sciences (SPSS). Mean and standard deviation of quantitative variables such as age and gender were calculated. Percentages were calculated for qualitative variables such as cases showing negative and positive TTF-1 expression

Results

There were 105 female patients (95.45%) and 5 male patients (4.55%). Mean age of the female patients was 49.38 ± 11.19 years. Mean age of male patients was 62.40 ± 2.30 years. A total of 6 (5.45%) cases were positive for TTF-1 as compared to n=104 (94.5%) negative cases.

Table-1: TTF-1 expression according to age.

TTF-1		Positive	Negative	Total
Age Catagory	25-45	4	43	47
	46-65	2	61	63
Total		6	104	110

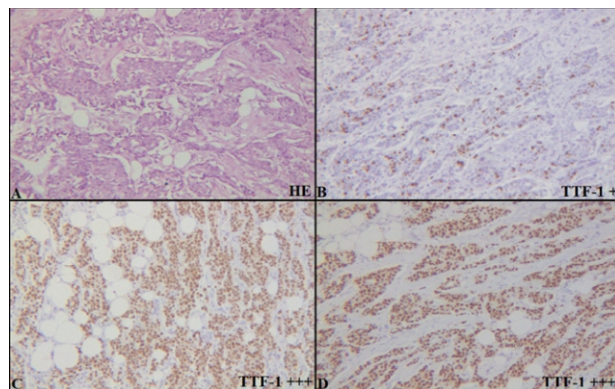


Fig-1: Breast carcinoma tissue at 10X A) Hematoxylin-Eosin staining B) TTF-1 nuclear expression showing weak positivity C, D) TTF-1

nuclear expression showing strong positivity Sensitivity is calculated as in our previous study.²³ All the cases were diagnosed BC and no controls were available, hence, we calculated sensitivity only.

$$\text{Sensitivity} = \frac{\text{Total positive cases}}{\text{Total positive cases} + \text{False negative cases}} \times 100$$

$$= \frac{104}{104 + 6} \times 100 = 94.54\%$$

The data was stratified according to age and gender. Chi-square test was applied with significant results kept at $p=0.05$. There was no significant association between TTF-1 expression in males and females and different age groups ($P=0.143$ for gender and $p=0.223$ for age groups) (Table 1).

Discussion

In our cross sectional study 110 cases were selected according to our inclusion criteria and TTF 1 IHC stain was applied. A total of 6 cases were positive for TTF 1 that is 5.5 % which is quite comparable with previous studies conducted by Klingen *et al*²⁴ and Robin *et al*²⁵ that is 2.8% and 2.4 % respectively. The problem of differentiating primary breast carcinomas from lung carcinomas has become more complex as both tumors are positive for Immuno-histochemical stain Cytokeratin 7.²⁶ As we know now according to our study and different other studies carcinomas of breast origin can also stain positive for TTF 1, so it has become extremely important to evaluate this stain in context of detail clinical detail. The other clinical details that are required in proper diagnosing a tumor and its site of origin are previous history of any lesion and tumor, histological findings of previous tumor if sampled before, complete radiological findings including the findings of breast and lung.²⁷

Breast tumors have a tendency to metastasize to the lungs however it is quite rare that a primary lung tumor metastasize to breast. As we know that the treatment modalities of both breast and lung tumors are quite different from each other so extreme precautions should be taken in labeling a tumor its primary site.²⁸ In our study a significant number of breast tumors are positive for TTF-1 IHC stain that is commonly observed stain in lung tumors. Here, this has become important to see this TTF1 stain with caution in background

clinical and radiological details. This will go a long way in deciding the option of treatment in patients. Studies from both Klingen et al and Robin et al shows that they use SPT24 clone of TTF1 stain while another study by Sakurai et al use clone 8G7G3/1 that shows 03 % positivity for primary breast carcinomas.²⁹ The procedure that has been applied and clone of antibody can have an effect on the results however all the studies shows that TTF 1 stain was positive in a significant number of cases including ours. The clone we use in our study was applied in an automated DAKO strainer.

There are different radiological findings that are quite helpful in deciding whether the tumor is primary or metastatic.³⁰ There are certain peculiar features that supports either the lesion is primary or metastatic. These findings should always be used along with detail clinical information, histological findings and immunohistochemical workup of the biopsy. While diagnosing primary breast and lung lesions other sites if involved should be considered as possible primary sites.

According to results from Klingen et al 04 out of 07 positive cases were of higher grade (Grade 3) while few studies also shows that tumors with basal like morphology shows more percentage of TTF1 positivity. In our institute breast tumors were not further categorized and finding association with basal like morphology was beyond the scope of our study however most of the tumors that are positive for TTF1 in our study are of higher grade. Our study also includes five male patients with breast tumors and shows one case with TTF1 positivity. However no significant gender association was noted in our results. Breast tumor is far more common in female patients but quite a few numbers of cases are also seen in male patients. While dealing with tumors of unknown origin in male patient possibility of primary breast tumors should also be considered and TTF1 positivity does not rule out the possibility of primary breast carcinomas. The major studies about TTF1 positivity in breast tumors like we discussed before by klingen et al and Robin et al did not specify the gender of patients. Thyroid transcription factor 1 (TTF1) is expressed in different normal tissues like type II pneumocytes of lung parenchyma, follicular cells of thyroid and subsets of bronchiolar cells that's why it is considered a reliable marker for primary

lung and thyroid tumors. It is being reported over the years that this TTF 1 is also positive in tumors arising from female genital, upper GIT and other extra-pulmonary sites.³¹

Males and females of different age groups (25-65 year) were included in our study and age relation with TTF1 positivity of breast tumors were calculated. In a group between 25 to 45 years of age 04 out of 47 cases were positive and the group that includes patient from 45 to 65 years show 02 out of 63 cases were positive for TTF1. The result shows no significant stratification of TTF1 positivity with the age of patients.

Every tumor has a specific tendency to metastasize to distant sites. Regional lymph nodes are the one that at first usually receive metastatic deposits. Both lung and breast tumors can metastasize to supraclavicular lymph nodes. The metastatic deposits are usually poorly differentiated. Metastatic tumors site of origin is poor differentiation. Here the role of immunohistochemistry is very important in further categorization of tumors and our study will help in correct identification of these metastatic deposits.

Conclusion

In conclusion, TTF-1 expression is seen in a small proportion of breast carcinomas. Thus, the presence of TTF-1 immunoreactivity cannot by itself be used to rule out a breast origin in a carcinoma of unknown primary site. These results emphasize the potential pitfall of relying on the results of a single immunostain to establish the site of origin of a carcinoma in a patient without a known primary site.

Conflict of interest: Authors declare no conflict of interest.

References

1. Toss MS, Miligy I, Al-Kawaz A, Alsleem M, Khout H, Rida PC, et al. Prognostic significance of tumor-infiltrating lymphocytes in ductal carcinoma in situ of the breast. *Modern Pathol.* 2018; 31(8): 1226.
2. Arshad S, ur Rehman M, Abid F, Yasir S, Qayyum M, Ashiq K, et al. Current situation of breast cancer in Pakistan with the available interventions. *Int J Biosci.* 2019;11(6):232-40.

3. Khan ZU, Khan RA, Muhammad B, Ullah H, Ullah A, Ahmed M. Prevalence of breast cancer in southern part of KPK Pakistan hospital BINOR based study. *J Pak Med Assoc.* 2018; 68(3): 499-500.
4. Samoon Z, Beg M, Idress R, Jabbar AA. Survival and treatment outcomes of metaplastic breast carcinoma: Single tertiary care center experience in Pakistan. *Indian J Cancer.* 2019; 56(2): 124.
5. Perusquía KYG, Bautista JCP. Delayed Access to Medical Care of Patients with Breast Cancer. *Mex J Med Res.* 2018; 6(11).
6. Ali RH, Taraboanta C, Mohammad T, Hayes MM, Ionescu DN. Metastatic non-small cell lung carcinoma a mimic of primary breast carcinoma—case series and literature review. *VirchArch.* 2018; 472(5): 771-7.
7. Srivastava P, Kumar B, Joshi U, Bano M. To evaluate the applicability of parameters of cytological grading systems on aspirates of breast carcinoma. *J Cytol.* 2018; 35(1): 15.
8. Rakha EA, Aleskandarani M, Toss MS, Green AR, Ball G, Ellis IO, et al. Breast cancer histologic grading using digital microscopy: concordance and outcome association. *J Clin Pathol.* 2018; 71(8): 680-6.
9. Tang P, Bui MM, Peng Y. *Immunohistochemistry in Breast Cancer.* Pract Breast Pathol: Springer; 2019. p. 173-92.
10. Osamura RY, Matsui N, Okubo M, Chen L, Field AS. Histopathology and cytopathology of neuroendocrine tumors and carcinomas of the breast: a review. *Acta Cytologica.* 2019; 63(4): 340-6.
11. Bonfiglio R, Scimeca M, Toschi N, Pistolese CA, Giannini E, Antonacci C, et al. Radiological, histological and chemical analysis of breast microcalcifications: diagnostic value and biological significance. *J Mammary Gland Biol Neopl.* 2018; 23(1-2): 89-99.
12. Vag T, Steiger K, Rossmann A, Keller U, Noske A, Herhaus P, et al. PET imaging of chemokine receptor CXCR4 in patients with primary and recurrent breast carcinoma. *EJNMMI Res.* 2018; 8(1): 90.
13. Bai X, Ni J, Beretov J, Graham P, Li Y. Cancer stem cell in breast cancer therapeutic resistance. *Cancer Treat Rev.* 2018; 69(1): 152-63.
14. Viale G, De Snoo F, Slaets L, Bogaerts J, van't Veer L, Rutgers E, et al. Immunohistochemical versus molecular (Blue Print and MammaPrint) subtyping of breast carcinoma. Outcome results from the EORTC 10041/BIG 3-04 MINDACT trial. *Breast Cancer Res Treat.* 2018; 167(1): 123-31.
15. telow EB, Yaziji H. *Immuno-histo-chemistry, carcinomas of unknown primary, and incidence rates. Seminars in diagnostic pathology;* Elsevier; 2018. p. 143-52.
16. Trang D-N, Wang H, Nicolas M, Nazarullah A. Metastatic breast cancer with GATA3, CK7 and ER positivity? A diagnostic pitfall. *J Case Reports Im Pathol.* 2018; 4: 100021Z11DT2018..
17. Hui Y, Wang Y, Nam G, Fanion J, Sturtevant A, Lombardo KA, et al. Differentiating breast carcinoma with signet ring features from gastrointestinal signet ring carcinoma: assessment of immunohistochemical markers. *Hum Pathol.* 2018; 77(1): 11-9.
18. Kubo T, Hirohashi Y, Fujita H, Sugita S, Kikuchi Y, Shinkawa T, et al. Occult ovarian clear-cell carcinoma diagnosed as primary adenocarcinoma of the lung: A case report of a diagnostic pitfall for clinicians and pathologists. *Respir Med Case Rep.* 2018; 25(1): 306-8. PMC6205346
19. Sapino A. TTF-1 nuclear expression: small cell carcinoma or not? Kawasaki T, Bussolati G, Sugai T. 2019; DOI:10.1111/his.12482.
20. Phelps CA, Lai S-C, Mu D. Roles of thyroid transcription factor 1 in lung cancer biology. *Vitamins and hormones:* Elsevier; 2018. p. 517-44.
21. Bhargava R, Dabbs DJ. *Immunohistochemistry of metastatic carcinomas of unknown primary. Diagnostic Immunohistochemistry:* Elsevier; 2011. p. 206-55.
22. Su Y-C, Hsu Y-C, Chai C-Y. Role of TTF-1, CK20, and CK7 immunohistochemistry for diagnosis of primary and secondary lungadenocarcinoma. *The Kaohsiung J Med Sci.* 2006; 22(1): 14-9.
23. Perveen S, Mehboob R, Khan AA, Bukhari MH, Ahmad FJ. Novel strategy to diagnose and grade hepatocellular carcinoma. *Natural Sci.* 2013; 5(1): 9.
24. Klingen TA, Chen Y, Gundersen MD, Aas H

grade hepatocellular carcinoma. *Natural Sci.* 2013; 5(1): 9.

24. Klingen TA, Chen Y, Gundersen MD, Aas H, Westre B, Sauer T. Thyroid transcription factor-1 positive primary breast cancer: a case report with review of the literature. *Diagnost Pathol.* 2010; 5(1): 37.

25. Vollmer RT. Primary lung cancer vs metastatic breast cancer: a probabilistic approach. *Am J Clin Pathol.* 2009; 132(3): 391-5.

26. Bejarano PA, Mousavi F. Incidence and Significance of Cytoplasmic Thyroid Transcription Factor-1 Immunoreactivity. *Arch Pathol Lab Med.* 2003; 127(2): 193-5.

27. Moldvay J, Jackel M, Bogos K, Soltész I, Agócs L, Kovács G, et al. The role of TTF-1 in differentiating primary and metastatic lung adenocarcinomas. *Pathol Oncol Res.* 2004; 10(2): 85-8.

28. Klingen TA, Chen Y, Suhrke P, Stefansson IM, Gundersen MD, Akslen LA. Expression of thyroid transcription factor-1 is associated with a

basal-like phenotype in breast carcinomas. *Diagnost Pathol.* 2013; 8(1): 80.

29. Sakurai A, Sakai Y, Yatabe Y. Thyroid transcription factor-1 expression in rare cases of mammary ductal carcinoma. *Histopathol.* 2011; 59(1): 145-8.

30. Srodon M, Westra WH. Immunohistochemical staining for thyroid transcription factor-1: A helpful aid in discerning primary site of tumor origin in patients with brain metastases. *Hum Pathol.* 2002; 33(6): 642-5.

31. Shahid RK, Haider K, Sami A, Ahmad I, Arnold F, Yadav S, et al. Extra-pulmonary small cell cancer: diagnosis, treatment, and prognosis. *General Methods and Overviews, Lung Carcinoma and Prostate Carcinoma: Springer;* 2008. p. 207-17.

32. Compérat E, Zhang F, Perrotin C, Molina T, Magdeleinat P, Marmey B, et al. Variable sensitivity and specificity of TTF-1 antibodies in lung metastatic adenocarcinoma of colorectal origin. *Modern Pathol.* 2005; 18(10): 1371.