

Original Article

Bilateral Rhinosinusitis: The Incidence of Odontogenic InfectionsMohammad Iqbal,¹ Sahibzada Fawad Khan,² Sohail Khan,³ Sommaya Hanif,⁴ Wasim Ahmad⁴¹Department of ENT, Bannu Medical College Bannu-KP, ²Department of ENT, Nowshehra Medical College, Nowshehra-KP, ³Department of ENT, Saidu Medical College, Swat-KP, ⁴Department of Allied Health Sciences, SHS, Peshawar-KP**Abstract**

Objective: The present study was designed to evaluate the incidence of odontogenic infections in patients suffering from bilateral rhino sinusitis (paranasal sinuses) referred to allied teaching hospitals of BMC Bannu-KP.

Methods: It was a retrospective study that was conducted at ENT departments of Allied teaching hospitals of BMC Bannu-KP from January 2020 to January 2021. A total of 100 patients were enrolled for this study. The patients were enrolled based on their diagnosis of bilateral rhino sinusitis after enough clinical investigations and valid opacification on either side on maxillary sinuses image done by OP (orthopantomography) or CT (computed tomography). In addition to OP and CT, the Odontogenic sinusitis was determined through the examination of EP and oral findings.

Results: The study was done on 100 patients in which, 60% were male (n=60) whereas 40% were female (n=40). The Odontogenic infections were found to be involved in 28% (n=28) of patients in which, 18 (64.28%) were male with a mean age of 38.56 years and 10 (35.71%) were female patients with a mean age of 47.42 years. Unilateral Odontogenic was found to be involved in 16 patients (57.14%) whereas, bilateral Odontogenic infection was observed in rest of the 12 patients (42.85%). The infection was existed in few patients on both sides of the sinuses. In few patients, mycosis was observed whereas, sinusitis with polyps was also existing in patients with Odontogenic manifestations.

Conclusion: It is concluded that the diagnosis of patients having sinusitis associated with maxillary sinus opacification should be considered based on the presence of Odontogenic sinusitis on either side along with the presence of nasal polyps.

Keywords: Odontogenic infection, Unilateral rhinosinusitis, Opacification, Maxillary sinus

How to cite this:

Iqbal M, Khan SF, Khan S, Hanif S, Ahmad W. Bilateral Rhinosinusitis: The Incidence of Odontogenic Infections. J Pak Soc Intern Med. 2021;2(2):123-126

Corresponding Author: Dr. Wasim Ahmad

Introduction

Numerous symptoms are associated with chronic rhinosinusitis that is found to be involved with or without nasal polyps. These symptoms include nasal congestion, nasal obstruction, nasal blockage or discharge, anosmia, pressure and pain at face and a prolonged coughing in children usually more than 3 months.¹ CRS or chronic rhinosinusitis is a condition that occurs commonly and gets establishes bilaterally. The origin of most of the unilateral chronic sinusitis is either mycotic or Odontogenic in nature. Because of having mycotic or dental origin, a few cases of unilateral CRS may be associated with cancerous cells which must be taken into consideration during differential diagnosis.¹ Many researchers have revealed the presence of maxillary sinusitis characterized with Odontogenic infection in 10 to 40% of all the reported

Email: vazim4847@gmail.com

cases²⁻⁴ having effects on 75% of patients with symptoms of unilateral maxillary rhinosinusitis considered for some surgical treatments.⁵

Although, numerous researchers have reported the involvement of bilateral maxillary rhinosinusitis^{6,7}, it is most commonly seen in patients suffering from unilateral rhinosinusitis associated with a prolonged history of maxillary dental glitches or having some contemporary maxillary dental treatment history. Furthermore, the dental professionals, ENT specialists and radiologists overlook the odontogenic etiology as a reason for RS because of having poor harmony on pathological involvements to consider as being⁸. It was believed that the odontogenic sinusitis is corre-lated to dental environment⁹, but novel reports have assimilated the term into the definition of SCDDT (Sino-nasal Complications of Dental Disease or

treatment).¹⁰⁻¹²

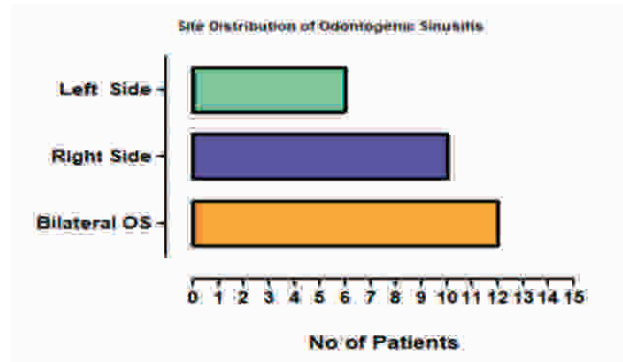
SCDDT and Odontogenic sinusitis is a resultant of compromised integrity of “Schneider’s membrane” by dental experts.^{13,14} As the mucoperiosteum gets disturbed, the microorganisms, specifically anaerobes etc. become more prone to cause infections ascending from the oral cavity¹⁵⁻¹⁷. The aim of this study was to assess the odontogenic pathologies that are involved in bilateral rhinosinusitis.

Methods

It was a retrospective study that was conducted at ENT departments of Allied teaching hospitals of BMC Bannu-KP from January 2020 to January 2021. A total of 100 patients were enrolled for this study. The patients were enrolled based on their diagnosis of bilateral rhinosinusitis after enough clinical investigations and valid opacification on either side on maxillary sinuses image done by OP (orthopantomography) or CT (computed tomography). In addition to OP and CT, the Odontogenic sinusitis was determined through the examination of EP and oral findings. The presence or absence of odontogenic infection was assured before doing the surgical procedure. The diagnosis of the rhinosinusitis was done in accordance with the guidelines of “European position paper”. All those patients were excluded from the study who scored less than 2 points on Lund-Mackay or those having sino-nasal, para-nasal tumors or cystic disease. All the cases having odontogenic infection were defined on the basis of their diagnosis⁵. The diagnosis was done with the help of CT, OP, electric pulp testing, intra-oral observation results etc. All cases possessing maxillary sinus opacification were gone through electric pulp testing. An otolaryngologist examined the sinus culture and endoscopic results. An oral surgeon investigated the engrossment of odontogenic infections in bilateral rhinosinusitis.

Results

The study was done on 100 patients in which, 60% were male (n=60) whereas 40% were female (n=40). The Odontogenic infections were found to be involved in 28% (n=28) of patients in which, 18 (64.28%) were male with a mean age of 38.56 years and 10 (35.71%) were female patients with a mean age of 47.42 years. Unilateral Odontogenic was found to be involved in 16 patients (57.14%) in which, it was found on the right side in 10 cases and on the left side in 6 cases whereas, bilateral Odontogenic infection was observed in rest of the 12 patients (42.85%). The infection was existed in few patients on both sides of the sinuses. In few patients, mycosis was observed whereas, sinusitis with polyps was also existing in patients with

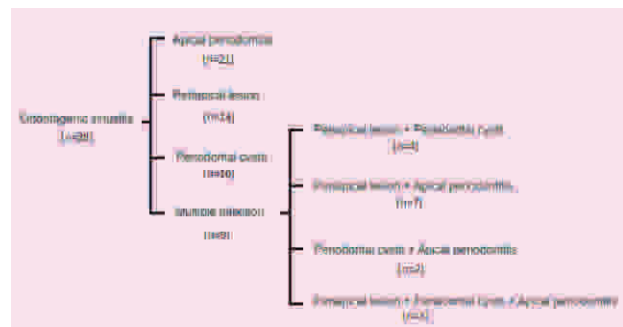


Odontogenic manifestations. Figure 1 below display the site distribution of odontogenic sinusitis in study population.

Figure 1. Site of Distribution of Odontogenic Sinusitis

Majority of the infections were initiated from the first molar (n=22), from 2nd molar (n=18), 2nd pre-molar (n=10), 1st pre-molar (n=5), lateral incisor (n=2), central incisor (n=1), canine (n=1), whereas the infection initiated from multiple teeth in 24 patients. The results from the imaging indicated 21 cases of apical periodontitis, 14 cases of periapical lesions, 10 cases of periodontal cysts and 9 cases with multiple infections. The detail of the multiple infections is given in the following.

Periapical lesion and periodontal cysts (n=4), Periapical lesion and apical periodontitis (n=7) Periodontal



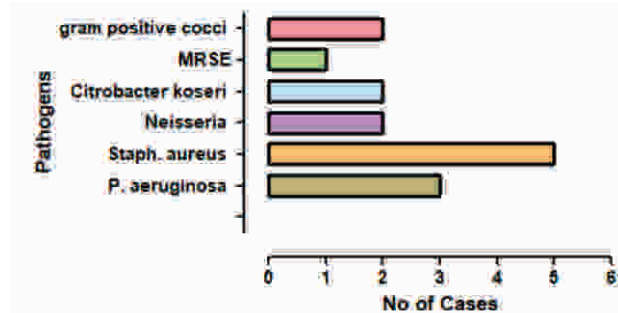
cysts and apical periodontitis (n=2), Periapical lesion, Periodontal cysts and apical periodontitis (n=3). The results are shown in figure 2 below.

Figure 2. Incidence of Pathologies in Odontogenic Sinusitis

Endoscopic examination of the nasal passages showed polyps and nasal discharge in 22 and 7 patients respectively. The patients with nasal discharge were subjected to culture test as well. The involvement of pathogens was found as: P. aeruginosa (n=3), Staph. aureus (n=5), Neisseria (n=2), Citrobacter koseri (n=2), MRSE (n=1), and gram positive cocci (n=2). The results are shown in figure 3 below.

19 cases had possessed polyps bilaterally (12 were

unilateral odontogenic infection and 7 were bilateral odontogenic infection), 6 cases had possessed polyps unilaterally and odontogenic infection were on the matching side of polyps. Nasal symptoms complaints were also recorded in patients including nasal discharge, obstruction and hyposmia each in a single patient.



Tooth pain and gum swelling was recorded in 3 patients only. Post-nasal drip was also observed in 2 cases. Results are shown in table 1 below.

Figure 3. Incidence of Multiple infections in Terms of Cases

Discussion

Chronic rhinosinusitis is observed mostly with bilateral opacification of the para-nasal sinuses. Its presentation

Table 1: Frequency of Complications in Study Population

Complications	No of Patients
Polyps observed bilaterally	19
Unilateral odontogenic infection	12
Bilateral odontogenic infection	7
Unilateral polyps	6
Tooth pain and gum swelling	3
Post-nasal drip	2
Hyposmia	1
Nasal obstruction	1

can be seen with numerous pathologies. These pathologies include acute neutrophilic inflammation which is induced due to bacterial infection or eosinophilic inflammation¹. There are numerous research reports that have shown odontogenic maxillary sinusitis as unilateral rhinosinusitis in its origin.⁷ The odontogenic infections are taken into account in the differential diagnostic techniques. Conversely, para-nasal mycosis and odontogenic sinusitis are omitted from the differential diagnostic techniques of bilateral rhinosinusitis, as they are typically related with unilateral rhinosinusitis.

Though, the pathologic alterations linked with odontogenic sinusitis might occur in a bilateral fashion, the

otolaryngologists must look into this condition in those patients having para-nasal bilateral opacification. Numerous reports have shown the frequency of odontogenic maxillary sinusitis that overlaps with that of unilateral rhinosinusitis. Although, there is no data available earlier, we have shown the connection of odontogenic infection in bilateral sinusitis with maxillary sinus opacification on at least one side.

In our study, 100 patients with sinusitis were examined possessing at least a single maxillary sinus opacification and numerous maxillary sinus opacification on both sides. The selection of the patients was done on the basis of their symptoms, CT, OP, intra-nasal investigations, electric pulp testing and intra-oral findings. Both otolaryngologist and an oral surgeon were present for their examination. Out of 100 patients, 28 patients with bilateral sinusitis observed with odontogenic sinusitis. Unilateral Odontogenic was found to be involved in 16 patients (57.14%) in which, it was found on the right side in 10 cases and on the left side in 6 cases whereas, bilateral Odontogenic infection was observed in rest of the 12 patients (42.85%). Multiple teeth were stood responsible for unilateral or bilaterally. In all the 28 cases, the spreading inflammation from the teeth to the apical area was considered as a reason of sinusitis. A researcher findings showed the presence of bilateral manifestations in 7.4% patients.⁷ Another study had shown the incidence of unilateral maxillary opacification in 94.5% patients in comparison to bilateral inflammation which was 5.4% only. More or less 30.2% of patients shown a bilateral odontogenic focus whereas, the remaining showed a history of unilateral dental pathologies. This was based on findings of 480 patients.⁹ Numerous studies have displayed the frequency of maxillary sinusitis having odontogenic origin from 10 to 40%.²⁻⁴

As refractory pathology is supposed to be involved in odontogenic sinusitis, the patients with rhinosinusitis with polyps were more in our study population. During follow-up time period, mild opacification on maxillary sinus was confirmed. The results are in consistency with the findings of certain researchers.¹¹ In our study, the improved clinical results were obtained because of dental treatment procedures. Based on our clinical findings, it is recommended that one should take care about the probability of complications associated with odontogenic infection induced neutrophilic inflammation additionally with the eosinophilic inflammation.

Conclusion

Bilateral rhinosinusitis is a complication on which limited data is available and this is in comparison to unilateral rhinosinusitis. It is concluded that the diagnosis of patients having sinusitis associated with

maxillary sinus opacification should be considered based on the presence of Odontogenic sinusitis on either side along with the presence of nasal polyps.

Conflict of Interest

None

Funding Source

None

References

1. Fokkens WJ, Lund VJ, Hopkins C, Hellings PW, Kern R, Reitsma S, et.al. European position paper on rhinosinusitis and nasal polyps 2020. *Rhinology*. 2020;58(29): doi: 10.4193/Rhin20.600.
2. Brook I. Sinusitis of odontogenic origin. *Otolaryngology-Head Neck Surg*. 2006;135(3):349-55.
3. Melén I, Lindahl L, Andréasson L, Rundcrantz H. Chronic maxillary sinusitis: definition, diagnosis and relation to dental infections and nasal polyposis. *Acta Oto-laryngologica*. 1986;101(3-4):320-7.
4. Mehra P, Murad H. Maxillary sinus disease of odontogenic origin. *Otolaryngologic Clinics of North America*. 2004;37(2):347-64.
5. Troeltzsch M, Pache C, Troeltzsch M, Kaeppler G, Ehrenfeld M, Otto S, Probst F. Etiology and clinical characteristics of symptomatic unilateral maxillary sinusitis: a review of 174 cases. *J Cranio-Maxillo-facial Surg*. 2015;43(8):1522-9.
6. Saibene AM, Pipolo GC, Lozza P, Maccari A, Portaleone SM, Scotti A, Borloni R, Messina F, Di Pasquale D, Felisati G. Redefining boundaries in odontogenic sinusitis: a retrospective evaluation of extramaxillary involvement in 315 patients. *Int Forum Allerg Rhinol*. 2014; 4(12):1020-3.
7. Vinciguerra A, Saibene AM, Lozza P, Maccari A. Unusual case of bilateral maxillary fungus ball. *Case Reports*. 2016;2016:bcr2016217930.
8. Lee KC, Lee SJ. Clinical features and treatments of odontogenic sinusitis. *Yonsei Med J*. 2010;51(6):932.
9. Felisati G, Chiapasco M, Lozza P, Saibene AM, Pipolo C, Zaniboni M, et.al. Sinonasal complications resulting from dental treatment: outcome-oriented proposal of classification and surgical protocol. *Am J Rhinol Allergy*. 2013;27(4):e101-6.
10. Chiapasco M, Felisati G, Zaniboni M, Pipolo C, Borloni R, Lozza P. The treatment of sinusitis following maxillary sinus grafting with the association of functional endoscopic sinus surgery (FESS) and an intra-oral approach. *Clin Oral Implants Res*. 2013;24(6):623-9.
11. Chiapasco M, Felisati G, Maccari A, Borloni R, Gatti F, Leo FD. The management of complications following displacement of oral implants in the paranasal sinuses: a multicenter clinical report and proposed treatment protocols. *Int J Oral Maxillofac Surg* 2009;38(12):1273-8.
12. Fadda GL, Berrone M, Crosetti E, Succo G. Monolateral sinonasal complications of dental disease or treatment: when does endoscopic endonasal surgery require an intraoral approach?. *Acta Otorhinolaryngologica Italica*. 2016;36(4):300.
13. Felisati G, Saibene AM, Lenzi R, Pipolo C. Late recovery from foreign body sinusitis after maxillary sinus floor augmentation. *Case Reports*. 2012; doi: 10.1136/bcr-2012-007434.
14. Račić A, Dotlić J, Janošević L. Oral surgery as risk factor of odontogenic maxillary sinusitis. *Srp Arh Celok Lek*. 2006;134(5-6):191-4.
15. Finegold SM, Flynn MJ, Rose FV, Jousimies-Somer H, Jakielaszek C, McTeague M, Wexler HM, Berkowitz E, Wynne B. Bacteriologic findings associated with chronic bacterial maxillary sinusitis in adults. *Clin Infect Dis*. 2002;35(4):428-33.
16. Saibene AM, Di Pasquale D, Pipolo C, Felisati G. Actinomycosis mimicking sinonasal malignant disease. *Case Reports*. 2013; [http://dx.doi.org/ 10.1136/bcr-2013-200300](http://dx.doi.org/10.1136/bcr-2013-200300)
17. Drago L, Vassena C, Saibene AM, Fabbro MD, Felisati G. A case of coinfection in a chronic maxillary sinusitis of odontogenic origin: identification of *Dialister pneumosintes*. *J Endod* 2013;39(8):1084-7