

Case Report

Bradycardia with Remdesivir Therapy for Covid-19 Pneumonitis

Malik Asif Humayun

Consultant Physician, UK.

How to cite this:

Humayun MA. Bradycardia with Remdesivir Therapy for Covid-19 Pneumonitis. J Pak Soc Intern Med. 2022;3(1):58-62

Corresponding Author: Dr. Malik Asif Humayun

DOI: <https://doi.org/10.70302/jpsim.v3i1.2212>

Introduction

Sinus bradycardia is defined as a rhythm arising from the SA node at a lower rate than normal, below 60 beats per minute (Normal sinus heart rate is 60-100 beats per minute).¹ Bradycardia occurs in healthy persons as part of an adaptive response particularly in athletes, during sleep, in children and the elderly.¹ Pharmacological agents are one of the most common causes of bradycardia.¹ Covid -19 is an acute respiratory syndrome caused by the SARS –CoV2 coronavirus and has been the cause of a global pandemic since 2019 till present .

Remdesivir is an antiviral agent approved for the treatment of Covid-19 by the United States Food and Drug Administration (FDA) and the United Kingdom Department of Health and Social care. The aim of this case presentation is to highlight the occurrence of cardiac side effects with use of Remdesivir and emphasize the need for baseline ECG prior to start of treatment and regular heart rate (HR) monitoring during therapy.

Case Presentation

44 year old man who was previously fit and well, developed symptoms of cough, fever, pleuritic chest pain and hemoptysis of 2 days duration prior to presentation. History of increasing shortness of breath along with myalgia, fatigue and reduced urine output. On examination, he had low oxygen saturations -87% on room air which improved to 94% on 2L of oxygen, bilateral crepitations and reduced air entry. Observations done showed pyrexia of 38.9, blood pressure of 93/58mmHg, respiratory rate 16 and HR-93 beats per minute. He had normal heart sounds and abdominal examination fin-dings. He worked as a lorry driver and lives with his family. Wife and daughter had recently tested positive for Covid-19.

Investigations

He tested positive for the Covid -19 virus two days prior to his hospital admission. Chest

Email: doctormalikasif@gmail.com

–Xray done showed patchy hazy airspace shadowing in mid and lower zones bilaterally in a predominantly peripheral distribution in keeping with Covid pneumonitis.

Laboratory Findings

Table 1: Renal function tests while on Remdesivir

Bloods		Day 1	Day 2	Day 3	Day 4
Renal function	Sodium	134	137	136	137
	Potassium	4.1	4.8	4.5	4.4
	Urea	6.2	7.2	8.3	8.6
	Creatinine	110	80	79	96
	eGFR	63	>90	>90	74

Table 2: Liver Function Tests while on Remdesivir

Liver Function Test		Day 1	Day 2	Day 3	Day 4
Liver function Tests	Bilirubin	17	17	16	19
	ALT	62	70	51	79
	GGT	81	129	103	96
	ALP	53	68	59	59
	Total protein	60	63	66	72
	Albumin	37	37	38	40
	Globulin	23	26	28	32

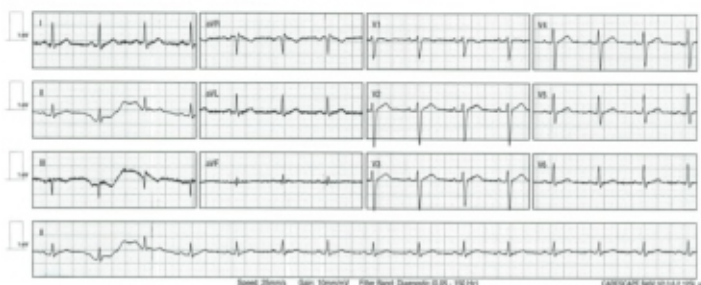

Figure 1

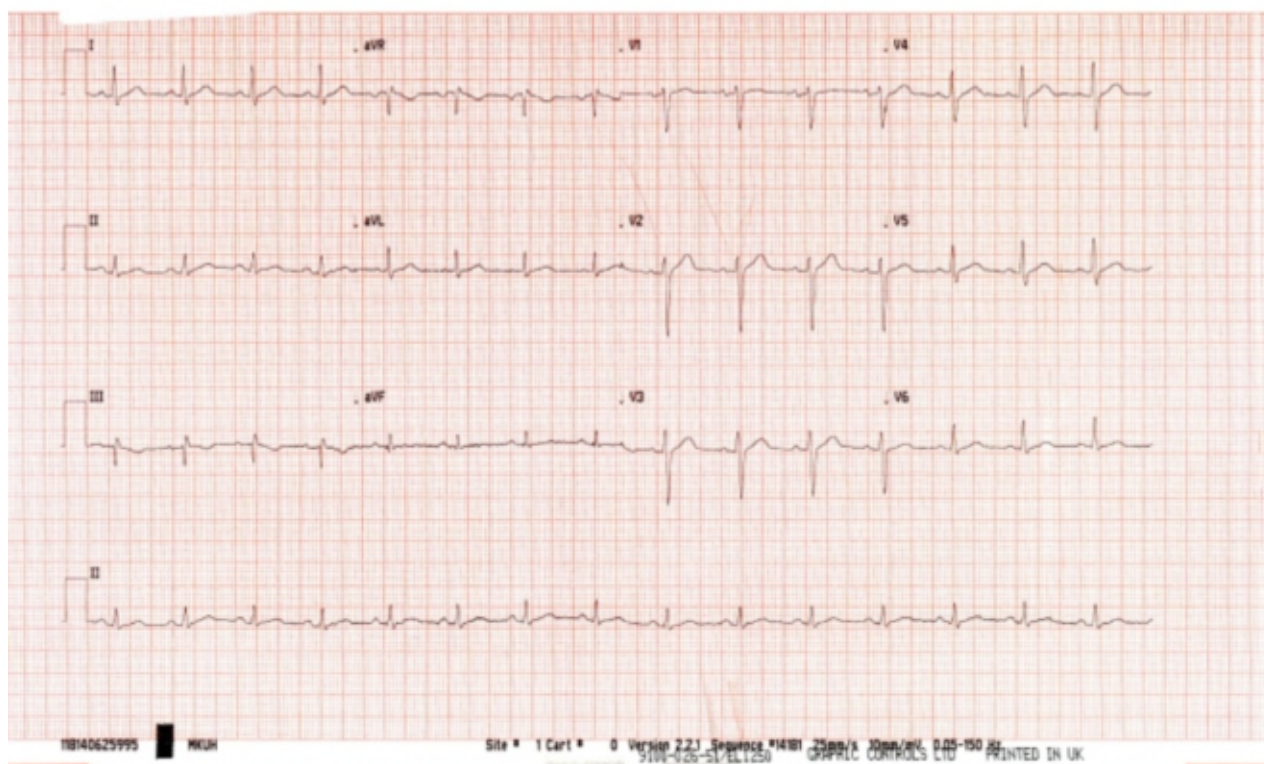


Figure 2

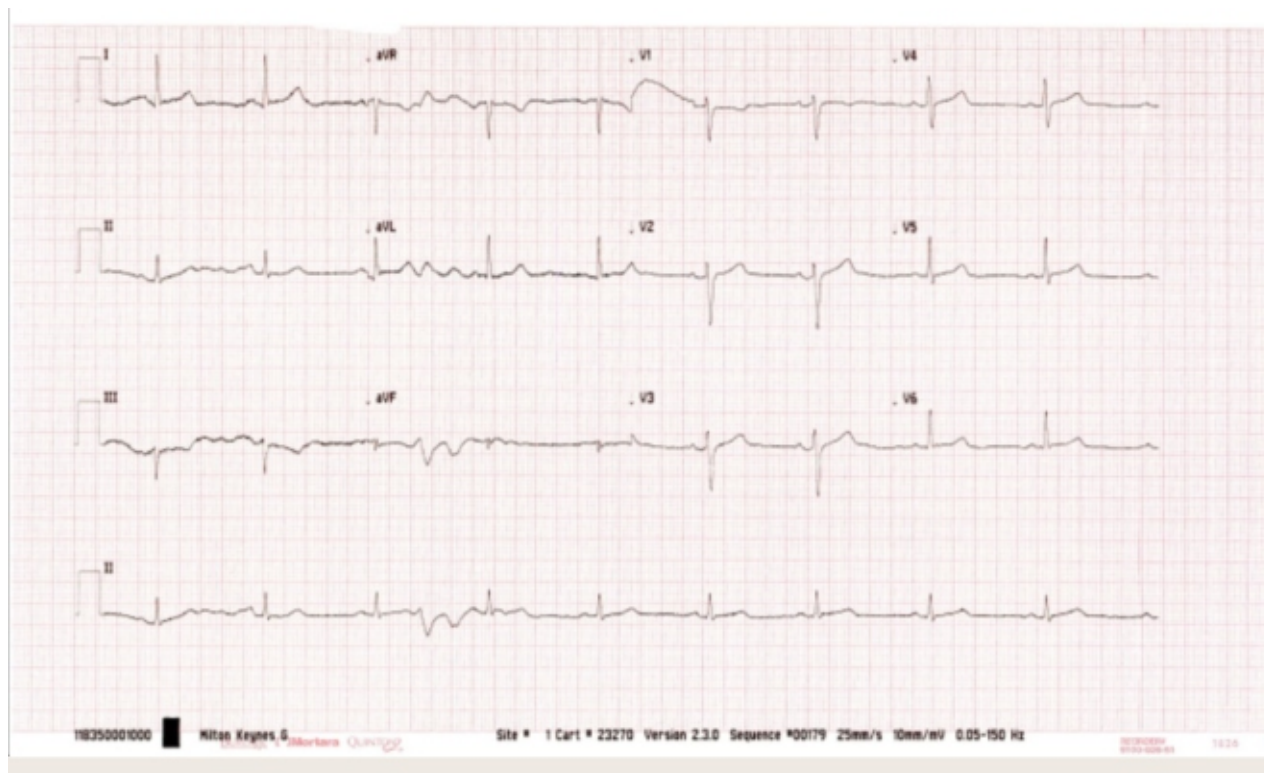


Figure 3

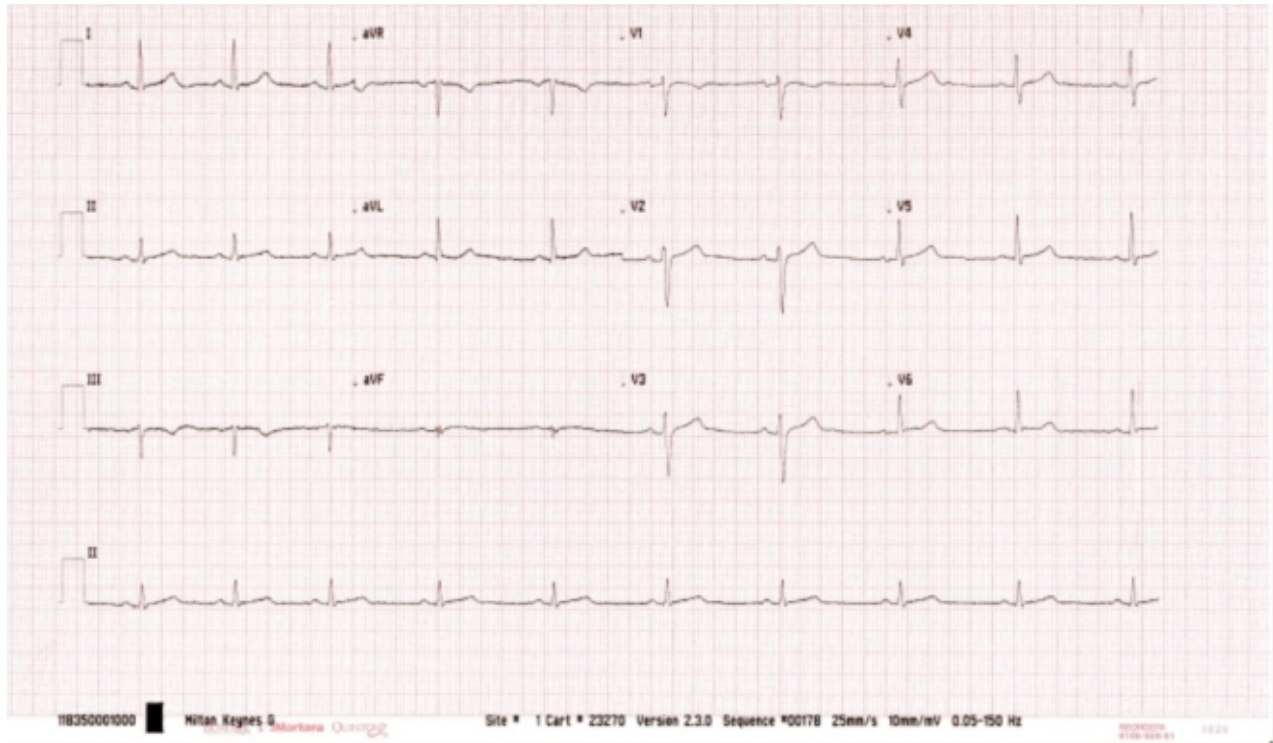


Figure 4

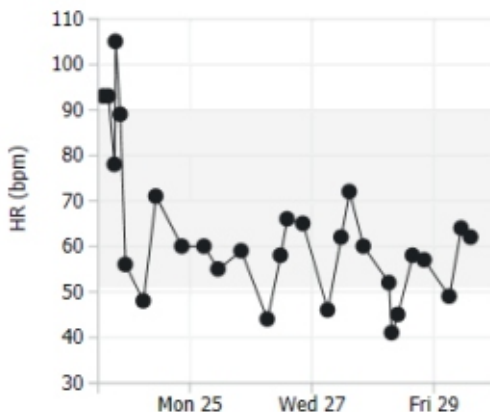


Figure 5

Graph of Heart rate during the days spent on admission. The patient was on Remdesivir from the 23rd of January 2021 to the 27th of January 2021.

Management

He was given intranasal oxygen via nasal cannula to maintain his oxygen saturations within the target range of more than 92%. A list of his medications during hospital stay is given in the table III. Remdesivir was started on Day1 of admission. It was prescribed as an initial loading dose of 200mg followed by 100mg daily for a total of five days with daily bloods to monitor renal function, clotting and liver function tests.

Patient was noted to have bradycardia 6 hours after the initial loading dose of Remdesivir. The patient’s heart rate fluctuated during the course of his treatment with

Remdesivir, varying between 41-72 beats per minute. He remained hemodynamically stable for the entire duration of his therapy. Other observations ranged as follows; blood pressure-92/62mmHg to 120/69mmHg, respiratory rate-16 to 25cycles per minute, oxygen saturations-91% on 4L of oxygen via nasal cannula to 96% on room air, and temperature improved from 39.3 degrees Celsius to 36.1 degrees Celsius.

Table 3: Regular medications

Medication	Dose	Start date
Dexamethasone tablets	6mg once a day	23 rd January 2021
Omeprazole capsules	20mg once a day	26 th January 2021
Intravenous Paracetamol	1gram four times a day for 3days	23 rd January 2021
Remdesivir infusion	200mg stat	23 rd January 2021
Remdesivir infusion	100mg once a day	24 th January 2021
Intravenous Co-amoxiclav	1,200grams every 8hours	23 rd January 2021
Subcutaneous Dalteparin	5000 i.u once a day	24 th January 2021

Table 4: PRN Medications (PRN-Pro re nata)

Medications	Dose	Start date
Paracetamol tablets	1gram prn (maximum of four times a day)	26 th January 2021

The patient had asymptomatic bradycardia for the entire duration of his hospital stay. He had bradycardia for a total of 5 days. After the discontinuation of Remdesivir, the bradycardia persisted for 2 days, with a slight improvement in heart rate from 49 to 64 beats per minute prior to discharge. He was weaned off oxygen, and then discharged home on oral antibiotics with a 2 week course of Apixaban. He is for follow up chest x-ray in 6 weeks and repeat Liver function tests with his Gp in 2 weeks.

Discussion

Remdesivir is an antiviral drug that is approved for compassionate use in COVID-19 patients requiring supplemental oxygen.² Its effects are exerted by limiting the action of SARS-COV-2 RNA dependent polymerase (RdRp) via intracellular delayed chain termination and hence limiting replication of the virus.

Remdesivir does not have a long list of well recognized side effects, partly due to its relative novelty only being approved for use in 2020.² In humans, Remdesivir has been associated with transaminase elevations, thrombocytopenia, hypersensitivity, rash, headache, nausea, whilst nephrotoxicity has been observed in animal studies.² This case is noteworthy as it also highlights bradycardia as an adverse effect to Remdesivir. The evidence for Remdesivir's cardiac side effects is sparse but growing. Other associated cardiac adverse events include atrial fibrillation, hypotension and cardiac arrest.³

To date we have found five cases of bradycardia in the literature, that have been attributed to Remdesivir in COVID-19 patients. Four of the cases consisted of adults between 26 and 77 years of age, and one was a child 13 years of age. The baseline heart rates across the cases were between 60 and 100 bpm and after administration of Remdesivir their heart rates dropped to rates between 34 and 48 bpm. It is important to note that in one of the cases Azithromycin was given concurrently, and in another Azithromycin was stopped shortly before Remdesivir administration.⁴ In one of these two cases, the QT interval did increase which is also a well-recognized side effect of Azithromycin.⁴

In four of the studies, Remdesivir was given as a 200mg loading dose on the first day of initiation, followed by 100mg once a day (OD); however in the report by Barkas et al it was stated that 100mg four times a day (QDS) was given after the loading dose of 200mg.⁵

In one of the cases, bradycardia occurred within 24 hours of the first dose of Remdesivir.⁶ In another bradycardia occurred on the second day of treatment, and in the other three cases, bradycardia was identified on day.³

In terms of bradycardia resolution, one resolved within 24 hours of stopping Remdesivir⁷, in two cases it took

two days¹¹, in one study resolution occurred within the "following days" (in this study the patient also received Atropine), and in one case it took nine days (in this case the patient had been on QDS Remdesivir as opposed to OD, which may be related to the delayed recovery time).⁵

Only one case mentioned cardiovascular co-morbidities (hypertension and left bundle branch block).⁶ This was also the only case in which another adverse cardiovascular effect was mentioned after Remdesivir initiation (hypotension). As part of our literature search we found two more cases that were not discussed above, as we did not feel that bradycardia could be clearly be attributed to Remdesivir. The first was the case of a newborn who developed bradycardia on day 3 after Remdesivir initiation (6th day of life). The patient had also received dexmedetomidine.⁷ In the other case, the patient developed hypotension, bradycardia and passed away on the same day making it difficult to establish whether bradycardia was due to Remdesivir or progression of severe COVID disease.⁸ The authors did not attribute bradycardia to Remdesivir in either of these two cases.

In our case the patient did not have any cardiovascular co-morbidity. He was not on any other drug which could be causing bradycardia. His heart rate on admission was 90bpm and QTc was 406ms. After initiation of Remdesivir his heart rate dropped to 56bpm with a QTc of 419ms. The lowest recorded heart rate was 41 bpm. He received only four Remdesivir doses, and his heart rate returned to normal approximately 36 hours after cessation. He did not experience any other cardiovascular complications.

Adverse effects of Remdesivir on the cardiovascular system have been shown to occur in a few studies. An example of this is seen in the use of Remdesivir against Ebola virus infection in a Randomised controlled study whereby out of 175 patients, 1 patient died of Hypotension and cardiac arrest.⁹ However, the authors could not ascertain if the cause of death was due to the Ebola virus itself.

A randomized control trial of 233 patients reported 1 patient had a cardiac arrest during Remdesivir therapy for Severe Covid while the placebo group reported none.³ The Adaptive Covid -19 Treatment Trial (ACTT-1) reported a 1.1% incidence of cardiac arrest in the experimental group compared to 1% in the control group. Atrial fibrillation was also seen to occur in 4% of the experimental group.³

Plausible mechanisms for the cardiovascular effects seen with Remdesivir could be, due to it being a nucleoside analogue similar to adenosine triphosphate. The endogenous nucleoside Adenosine has intrinsic anti-arrhythmic activity. It slows conduction through the

AV node and interrupts AV reentrant pathways, which restore normal sinus rhythm, hence Adenosine is used pharmacologically for the management of supraventricular tachycardias. It may be worth considering further studies to assess such potentials in Remdesivir. The other constituents of the Remdesivir injection (Sulfo-butylether- β -cyclodextrin (SBECD), water, and small amounts of hydrochloric acid or sodium hydroxide) are not known to have any effects on cardiac function.⁶

Our case highlights bradycardia as an important and increasingly recognized side effect of Remdesivir, that is reversible after cessation of therapy. Sinus bradycardia associated with Remdesivir seems to occur with QT interval prolongation, and hence there may be an increased risk of cardiac arrhythmias and sudden cardiac death¹⁰, both of which have an already increased incidence in COVID-19 patients. Patients who require hospitalization and Remdesivir therapy may already be at an increased risk of developing bradycardia for other reasons such as presence of ischaemic heart disease, autonomic dysfunction, administration of other rate controlling agents and COVID-19 itself.

We hope that our study will add to the growing evidence from which guidance can be produced to stay extremely cautious of the cardiovascular effects, especially bradycardia with Remdesivir therapy. This may require baseline heart rate and ECG testing to screen patients for bradycardia and QTc prolongation and ongoing regular HR and ECG monitoring.

Conflict of Interest: None

Funding Sources: None

References

- Munther K Homoud, MD, Jonathan Piccini, Susan B Yeon. Sinus bradycardia. Updated and cited 2021] Available from website: [https://www.uptodate.com/contents/sinusbradycardia?search=sinus%20bradycardia&source=search_result&selectedTitle=1~150&usage_type=default&display_rank=1#H114].
- SheIwat A, MmTay J, Birnkrant D, Farley J. Cross-Discipline Team Leader, Division Director, and ODE Summary Review. FDA. Center for drug evaluation and research application number: 214787orig1s000 summary review. Gilead Sciences, Inc. August 7, 2020.
- Wang Y, Zhang D, Du G, Du R, Zhao J, Jin Y, et al. Remdesivir in adults with severe COVID-19: a randomized, double-blind, placebo-controlled, multicenter trial. *Lancet*. 2020;395(10236):1569-78.
- Gupta AK, Parker BM, Priyadarshi V, Parker J. Cardiac Adverse Events with Remdesivir in COVID-19 Infection. *Cureus*. 2020 Oct 24; DOI: 10.7759/cureus.11132
- Barkas F, Styla CP, Bechlioulis A, Milionis H, Liberopoulos E. Sinus bradycardia associated with remdesivir treatment in covid-19: A case report and literature review. *J Cardiovasc Dev Dis*. 2021;8(2):1–5.
- Gubitosa JC, Kakar P, Gerula C, Nossa H, Finkel D, Wong K, et al. Marked Sinus Bradycardia Associated With Remdesivir in COVID-19: A Case and Literature Review. *JACC Case Reports*. 2020;2(14):2260–4.
- Mendez-Echevarria A, Kinga-Amalia S. B & Calvo C, Severe sinus bradycardia associated with remdesivir in a child with severe SARS-COV-2 infection-reply. *Eu J Pediat*. 2021; <https://doi.org/10.1007/s00431-021-03952-0>.
- Ahmed M, Yousif A, Hamad G.O, El-Raheem A, Salih D, Mohamed I. Use of Remdesivir in The Treatment of COVID-19 Infection Among Sudanese Patients-Case Series. 2021; <https://doi.org/10.21203/rs.3.rs-153556/v1>
- Mulangu S, Dodd LE, Davey RT, Tshiani Mbaya O, Proschan M, Mukadi D, et al. A Randomized, Controlled Trial of Ebola Virus Disease Therapeutics. *N Engl J Med*. 2019; 381(24):2293–303.
- Kuck KH. Arrhythmias and sudden cardiac death in the COVID-19 pandemic. Vol. 45, Herz. Springer Medizin; 2020. p. 325–6.