

Review Article

Clinicopathological Aspects and Management of Psoriasis

Asif Hussain

Consultant Physician, Clinical Director, Epping Medical Specialist Centre, Australia

Abstract

Psoriasis is a common rheumatological disease worldwide. It has many articular and extra-articular complications associated with comorbidities and mortality. It's often confused with other joint diseases such as rheumatoid arthritis. Also, various patterns of Psoriasis involving skin and joints make it a clinical puzzle that can mimic many diseases and pose a great difficulty for the diagnosis. Cutaneous and rheumatological complications contribute the most to morbidity and mortality and pose great difficulty managing Psoriasis. Though the advancement in the treatment of psoriasis arthritis has improved many articular complications, it has also increased the risk of many complications such as infections and drug-related toxicities. Recently there has been development in treating psoriatic arthritis and other seronegative arthritides, which are very different from those used for rheumatoid arthritis.

It's important to understand these differences for managing patients with psoriatic arthritis, which almost every doctor sees. This review article aims to provide insight into the pathogenesis of Psoriasis, its various manifestations, and its management in light of recent evidence.

Keywords: Psoriasis, psoriatic arthritis, seronegative arthritides, psoriatic nail disease, skin psoriasis.

How to cite this:

Hussain A. Clinicopathological aspects and management of Psoriasis. J Pak Soc Intern Med. 2022;3(3): 201-209

Corresponding Author: Dr. Asif Hussain

Email: drasifhussain@gmail.com

DOI: <https://doi.org/10.70302/jpsim.v3i3.2240>

Introduction**Psoriasis**

Psoriasis is a multisystem autoimmune disease affecting mainly the skin, nails, and joints. It's one of the five (SpA) spondylarthritides: Ankylosing Spondylitis (AS), Reactive Arthritis (ReA), Inflammatory Bowel Disease (IBD) related arthritis, and undifferentiated Spondylarthritides (USpA). Because of its wide variety of presentations can be a differential diagnosis of many skins and rheumatological diseases. It's often confused with other joint diseases such as rheumatoid arthritis, osteoarthritis, or seronegative arthritides. However, it shares some pharmacological treatments with other inflammatory arthritides like Rheumatoid Arthritis and SpA. Still, some treatment modalities are specific for Psoriasis, especially for skin involvement. Psoriasis has articular and extra-articular complications associated with comorbidities and mortality. Skin involvement has cosmetic and medical complications. Psoriasis has a strong association with metabolic syndrome.¹ Risk factors postulated for Psoriasis are family history, metabolic syndrome, drugs, smoking, alcohol, and may be infections.

Pathogenesis of Psoriasis

The flowsheet below shows a schematic process of the pathogenesis of Psoriasis. It involves entheses more than synovium, which is one of the main differences between Psoriasis and rheumatoid arthritis. Distal Interphalangeal Involvement (DIP) involvement in Psoriasis is a classic example, as the joint has many enthesial tissues.^{1,2} Fig. 1.

Pathogenesis of Psoriasis:

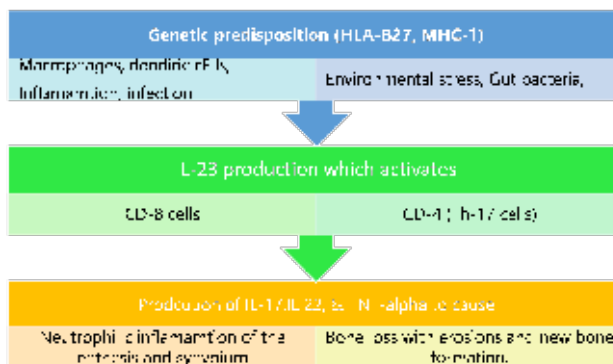


Fig.1: Pathogenesis of Psoriasis.

Abbreviations used: HLA (Human Leucocyte Antigen), IL (Interleukins), MHC (Major Histocompatibility

Complex), Th (T-helper cell), TNF (Tumour Necrosis Factor).

IL-23/IL-12 Cytokines Pathway for Spondylarthritides

Role of T-helper (Th) Th-1 & Th-17 T-Lymphocytes: T-helper-1 (Th-1) cells produce Tumour Necrosis Factor Alpha (TNF- α), Interferon (INF) gamma & Interleukin-2 (IL-2), which activate APC (antigen-presenting cells), Macrophages & T cells. IL-23 & IL-1 promote differentiation of naive T-cells into Th-17 cells. IL-6 & TGF- β also promote Th-17. Support for IL-23 is also required for the functioning of Th-17. These Th-17 produce IL-6, IL-17, IL-21, IL-22, INF-gamma, and TNF- α . IL-17 is critical in epithelial defense, including the epithelium's innate immunity.

Interleukin (IL)-23 & IL-12: IL-12 & IL-23 are needed for Th-1 & IL-17 is needed for Th-17 cells. These cells are vital for the pathogenesis of Psoriasis & similar diseases. IL-23 has a major role as a cytokine in causing the following diseases: Psoriasis, including Psoriatic arthritis (PsA), Ankylosing Spondylitis, Crohn's Disease, & Multiple Sclerosis (MS). IL-23 stimulates Th-cells 17 & CD-8 cells to produce IL-17, IL-22, & TNF- α . IL-22 causes epidermal proliferation and also new bone formation. IL-17 & TNF- α are major mediators for inflammation & damage through macrophages. Cytotoxic T-cells, osteoclasts, and synovial cells. IL-12 & IL-23 share a common part (p40).

IL-22 promotes growth factor production and increases epithelial proliferation, keratinization, acanthosis, and new bone formation. IL-23-dependent IL-22 production is an integral part of the immune defense against gram-negative bacteria. IL-22 works synergistically with other mediators like IL-17 & TNF- α & all of these are important mediators of inflammation and damage. IL-22R (IL-22 receptor) enhances coordination b/w IL-17 & IL-22.

Psoriatic Nail changes

Nail involvement is often many years later after skin Psoriasis. That may be a reason for less frequent nail changes in childhood Psoriasis. 5% of cases have only nail changes without skin involvement. Nail changes are strongly associated with joint involvement, especially DIP. This association could be due to biomechanical stress in the region or anatomical proximity. Fingernails are affected more than toenails due to rapid growth.³ [Fig3, Fig 5a].

Pathophysiological Basis of Nail Changes

The nail matrix is the tissue that produces nails. The proximal nail matrix is actively proliferating and proximal to & under the nail fold. Diseases of the proximal matrix destroy the whole nail as nail production is

affected. The distal matrix is in the nail bed (under the nail plate). A distal matrix and nail bed disease usually doesn't destroy the whole nail but causes other changes^[3,4].

Changes due to proximal matrix^{3,4,5,6}

Nail pits are due to tiny psoriatic patches in the proximal matrix producing abnormal keratin (parakeratosis). When they reach out of the nail fold, these parakeratotic patches drop off, leaving a tiny pit. If they don't drop off, it looks like Ivory-coloured spots in the proximal part of the nail plate. These pits are uniform in size and depth (unlike those caused by Fungus or trauma). They can be arranged haphazardly or in any pattern. Ten or more pits in one nail or >50 pits in all the nails are usually considered diagnostic. Red spots / erythematous lunula indicate dilated capillaries & active inflammation in the proximal matrix. Diseases of the proximal matrix destroy the whole nail as nail production is affected. Nail plate will be crumbled or even absent.

Nail fold changes

Nail fold, when involved by Psoriasis, can become swollen and rounded due to the inflammation. Thickened nail fold obscures the cuticle.

Distal Matrix/Nail-Bed changes^{3,5,6}

Salmon spots or oil drop spots are due to psoriatic patches under the nail plate in a distal matrix. This parakeratosis is pressed between the nail bed and nail plate and has serum. Hence, it gives the appearance of white paper (leuconychia) with an oil drop. The proximal margin may be red due to active inflammation of the psoriatic patch. This redness help differentiates it from other causes of leuconychia, oil spot approaches, or onycholysis. However, if the parakeratosis is too thick & dry, it doesn't have an oil spot appearance. Thick parakeratosis will cause a dystrophic thickened nail, which may be painful. When this parakeratosis reaches hyponychium, it drops off, leading to a broken nail (onycholysis). Leuconychia is a loss of the normal reddish look of the nail plate. This normal slight redness is due to underlying capillaries in the nail bed. Parakeratosis b/w nail bed and nail plate causes loss of the red glow & makes it look opaque (leuconychia).

Splinter hemorrhages are bleeding spots under the nail plate. The bleeding happens due to trauma to the dilated capillaries (Auspitz's sign). Yellow subungual spots are Munro's abscess under the nail plate. These are seen in pustular Psoriasis. Acrodermatitis Suppurativa Continua is seen in pustular psoriasis. It usually involves one digit but can affect multiple or all fingers & toes. The skin of the distal phalanx becomes red with pustules, and these pustules then migrate into the proximal nail matrix destroying the whole nail apparatus. It may just leave a smooth reddish tip of the finger.

Psoriatic pachydermoperiostosis

It usually affects the big toe, making it swollen and often painful. It resembles clubbing.

D/D & diagnosis of nail psoriasis: It is a clinical diagnosis. However, if it's not obvious or typical, it will need a biopsy to confirm it. Differentials include Nail diseases due to Fungus, trauma, vascular insufficiency, neuropathy, drugs, and age-related nail changes. Skin disorders like Eczema, lichen plants, alopecia areata, and others can also be confused. Reactive arthritis can also have nail changes resembling pustular Psoriasis.^{3,4,5,7}

Treatment of psoriatic nails: Topical treatment by a dermatologist. Systemic options s generally used for systemic diseases. Chemical synthetic Disease Modifying Rheumatoid Drugs (csDMARD), such as methotrexate (MTX), work well for Psoriasis. Leflunomide (Lef) & sulfasalazine (SLZ) are not very effective for skin psoriasis. Hydroxychloroquine (HCQ) can make skin psoriasis worse. Apremilast (PDE-4 inhibitor) and biological Disease Modifying Anti Rheumatoid Drugs (bDMARD) such as anti-tumor necrosis factor-alpha inhibitors (anti-TNF-a), IL-23/12 blockers. IL-17 inhibitors are effective.³⁻⁷

Skin & Psoriasis

Common sites include groins, extensor surfaces, hair-line on scalp, ears, natal cleft, etc. Skin lesions may be absent in 15%. In comparison, 30% of those with skin psoriasis have arthritis too. 10% of Reactive arthritis (ReA), Ankylosing Spondylitis (AS), and inflammatory bowel disease (IBD) related arthritis cases can have co-existing skin changes of Psoriasis. ReA may have similar skin changes. Pregnancy and steroid use can increase arthritis risk in patients with skin psoriasis.⁸⁻¹² [Fig 2].

Pathogenesis of Cutaneous Psoriasis

Psoriasis is lymphocytic and variable neutrophilic inflammation of the dermis and basal part of the epidermis. It is mainly in the area b/w the ridges where vessels are present. It spares the rete ridges, which are not damaged; instead, they get hyperplastic & elongated due to proliferation. The proliferation of the rete ridges causes hyperkeratosis, thickening of the skin and scales, etc. Atrophy of the area b/w the ridges brings the vessels close to the surface and easy to bleed (Auspitz sign). Neutrophilic infiltration of the epidermis makes Munro's micro abscess.^{8,9}

Subtypes of Cutaneous Psoriasis^{8,9,10,11,12,13}

Plaque Psoriasis (also called psoriasis vulgaris) is sharply demarcated red papules or plaques with non-coherent silvery scales on extensor surfaces such as elbows, knees, scalp, and back. Removing the scale will cause slight bleeding (Auspitz sign). Type I starts in teenagers

and has a genetic predisposition with HLA-Cw 0602. Adult-onset (type II) starts in 50 plus patients who doesn't have a genetic predisposition. D/D includes fungal infections, Cutaneous Lupus Erythematosus, mycosis fungicides, secondary Syphilis, and Eczema. Scalp psoriasis from Discoid Lupus Erythematosus (DLE) & Tinea capitis. Psoriasis Inversa is a subtype that involves flexural creases: intergluteal cleft, groin, umbilicus, axilla, & sub-mammary area. This flexural Psoriasis often has no or slight scaling & lesions are often macerated/fissured. Psoriasis inverses can confuse intertrigo, candidiasis, etc.

Guttate psoriasis: guttata means drop like. It may be a subtype of plaque Psoriasis as it occurs in young teens with multiple drops like small (<1cm) papules on the trunk, face & proximal limbs. These are usually triggered by strep infections and are self-limited in most cases.

Nail psoriasis: (like scalp and psoriasis Inversa) is associated with a higher rate of PsA Oil spots (yellow subungual nail discoloration), nail pits, onycholysis, onychodystrophy. D/D fungal infections.

Pustular Psoriasis: sterile pustules with or without systemic inflammatory s/s depending on the extent. A limited subtype of pustular Psoriasis involves palms & soles only. In contrast, the generalized form involves the trunk and limbs with pustules on erythematous skin. The patient may also have systemic constitutional symptoms. D/D includes bacterial infections, non-infective pustulosis, etc. It can co-exist with plaque psoriasis.

Psoriatic erythroderma: It's generalized erythema of the skin. It could be due to plaque psoriasis, or it can be a separate entity. Scales may be variable depending on the rapidity of onset. It's a life-threatening disease due to the risk of dehydration, loss of albumin, hypothermia, and superadded infection. D/D includes drug-induced erythroderma autoimmune erythroderma.

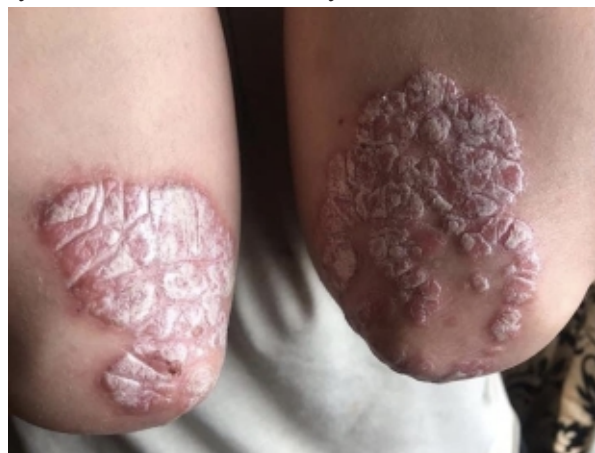

Fig.2: Plaque Psoriasis: silvery-white scales and erythematous plaques on the dorsum aspect of elbows.

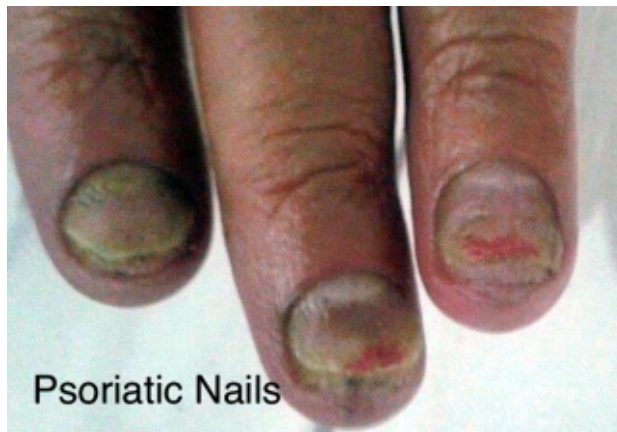

Fig. 3: Psoriatic nails.

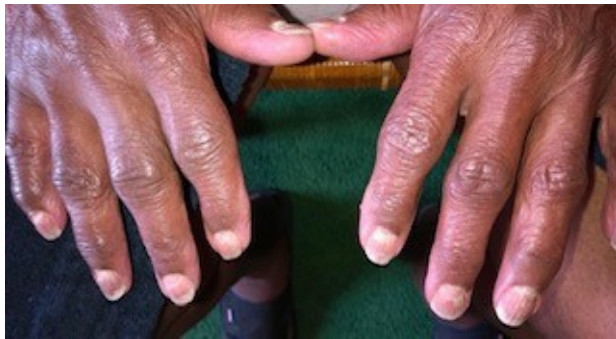

Fig. 4: Psoriatic arthritis & OA: Psoriatic nail changes are present too.

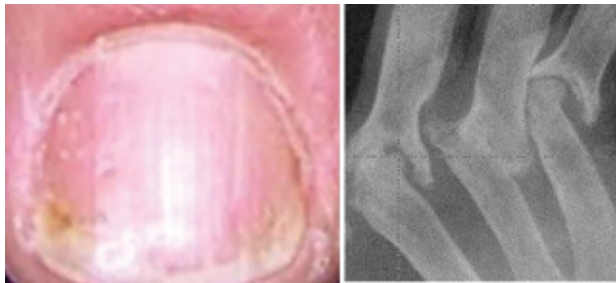


Fig5; Psoriatic Nail Changes (a) pitting, ridges, and discoloration., Arthritis mutilans with a classic pencil in a cup appearance (b)

Psoriatic Arthritis (PsA)

Juxta-articular bone resorption & new bone formation are characteristic features of PsA. Joint destruction is seen in 40-60%. Bone density is often preserved. Bone/joint ankylosis is common, whereas rheumatoid arthritis (RA) does not have new bone formation. Enthesitis is more prominent than synovitis.¹⁴

Patterns of Psoriatic Arthritis: Arthritis can mimic Rheumatoid Arthritis (RA). However, unlike RA, Psoriasis has a ray pattern of polyarthritis. It involves digits in a differential pattern: all the joints in the same digit are involved. In contrast, RA involves the same joints across all the digits. Psoriatic arthritis can mimic osteo-

arthritis (OA) involving distal interphalangeal joints (DIP) (like OA, Gout, or ReA). Arthritis Mutilans is osteolysis with telescoping of digits/toes. Arthritis Mutilans cause mutilation of articular bones & joint structures, leading to typical pencil in cup deformity with shortening of a finger. The base of the distal phalanx is sharpened like a pencil, and it fits into the middle phalanx (pencil is usually distal phalanx & cup is often middle phalanx but can be seen in any phalanx). PsA can also be like Spondylitis, such as Ankylosing or other Spondyloarthropathies. Other patterns can be monoarthritic (like gout or infections) or oligoarticular peripheral arthritis. These patterns may overlap or change with time.^{14,15} [Fig4, Fig 5b, Fig 6].

Syndesmophytes in Psoriatic Arthritis; These are asymmetrical & para marginal. Ankylosing Spondylitis has marginal and symmetrical syndesmophytes. Sacroiliitis (SI) & spine joint involvement in PsA is often asymmetrical & less destructive. Interspinous or anterior ligament calcification can also be seen. SI involvement is more with a longer duration of disease (50% in 10 years).^{14,15}

Dactylitis & Psoriasis: Toes or fingers are involved. It can be acute with redness or chronic without redness. It can also be seen in ReA, Scleroderma, and Sickle cell. Acute gout/cellulitis sometimes can be confused with dactylitis but later involves the whole digit.^{14,15}

Enthesitis & Psoriasis: plantar fasciitis, Achilles tendon, patellar tendon, iliac crest, epicondyles, and supraspinatus tendon are common sites for enthesitis. Tenosynovitis is also common. It can also be in Ankylosing Spondylitis (AS). Inflammatory clues on MRI include increased vascularity of the normally avascular tendon area. Other clues are soft-tissue oedema & bone marrow oedema of the adjacent bone. Doppler can also detect some of these changes.¹⁶

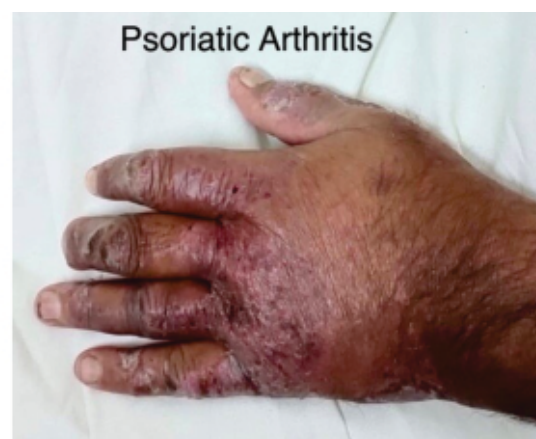

Fig. 6: Psoriatic Arthritis. Deformities of the Finger Joints at Proximal & distal Interphalangeal Joints with sparing of the MCP joints are obvious. The psoriatic skin rash is Present

D/D of Psoriatic Arthritis (PsA)¹⁴⁻¹⁷, [Table 1]:

Ankylosing Spondylitis (AS) vs. PsA: SI & spine is almost always involved and symmetrical in AS. Marginal syndesmophytes are symmetrical. Dactylitis and skin aren't involved in AS. Enthesitis is common in both. HLA-B27 is 90% (unlike PsA which is 30-40%).

Reactive arthritis (ReA) vs. PsA: Keratoderma blenorrhagicum, Balanitis circinate, previous GIT/genitourinary (GU) infection. HLA-B27 is positive in 70% of cases. Nail disease, DIP involvement, psoriatic rash, and Dactylitis can occur in ReA but are less

common. Significant confusion is b/w Psoriasis & Reiter's, as both involve nails, DIP joints, and the skin of the palms & soles, but erythematous plaques with silvery scales are only seen in Psoriasis. In contrast, balanitis is only seen in ReA. As Psoriasis rarely involves mucosal surfaces, conjunctivitis is also not seen in Psoriasis. So, the oral cavity, conjunctivae, and nasal mucosa are never involved in Psoriasis.

Rheumatoid arthritis (RA) vs. PsA: Ray distribution of arthritis, skin changes, new bone formation along with erosion, nail changes, Dactylitis, enthesitis, and

Table 1: Seronegative Arthritis: Clinical Difference of the Main Subtypes.

Disease	Joints (seronegative)	Addtl.nal clues	HLA-	Overlapping
Psoriatic Arthritis (PsA)	<i>Dip involvement</i> <i>Arthritis Mutilans Polvarthritis like RA</i> Seronegative Peripheral PolyarthritiS Spondylitis and SI involvement is often asymmetrical Syndesmophytes are asymmetrical and paramarginal	Nail changes Skin rash High Uric acid Uveitis Enthesitis Dactylitis	25-40%	10% may have colitis
Ankylosing Spondylitis (AS)	SI and Spondylitis is the main disease. Spondylitis and SI involvement is often symmetrical Syndesmophytes are symmetrical and marginal Peripheral seronegative can also be present.	Aortitis Apical lung fibrosis Uveitis Enthesitis	74-90%	10% may have colitis or psoriasis
Behcets Disease (BD)	Seronegative Arthritis: It is mono or oligoarthritis. It's non-deforming, transient & episodic, and the episode mostly resolves in a few days to weeks. Spondylitis	Oral & genital ulcers Thrombotic disease Vasculitis can mimic small, medium, or even large vessel patterns. Uveitis	None	Acneiform lesions Erythema Nodosum Non-genital skin ulcers Thrombophlebitis Vasculitic rash Pathergy test
Inflammatory Bowel Disease (IBD)	Type I (Peripheral, oligoarticular. parallel with bowel disease) Type II (Peripheral, smalljoints like RA but non-erosive, not affected by bowel disease) Spondylitis-not parallel with bowel disease. <i>Settle arthritis of SI or Hip</i>	Uveitis Enthesitis Dactylitis	less than 30%	Erythema nodosum
Reactive Arthritis (ReA). Previously called Reiter's syndrome	Arthritis is transient, fleeting. oligoarthritis of large joints of lower limbs more than the upper limbs. 25% of arthritis can become chronic & fixed. DIP involvement like PsA. Spondylitis (more common in HIA- B27 positive cases)	<i>Genitourinarv:</i> <i>Balanitis circinate, cervicitis. Urethritis ulcers, orchitis, eoididvmitis. PID Dvsenterv Coniunctivitis, Uveitis</i> Enthesitis Dactylitis	50-70./.	10% have psoriasis

Abbreviations used in Table 1: DIP (Distal Interphalangeal Joints), PID (Pelvic Inflammatory Disease), RA (Rheumatoid Arthritis), SI (Sacroiliac joint),

uveitis in PsA help differentiate. Bone formation is firmly against RA. Synovial involvement is often secondary to extra synovial involvement in PsA, and MRI may detect this. Extracapsular Inflammation on Gadolinium MRI (oedema at enthesis) favors PsA over RA.

Additional Manifestations of Psoriasis

Uveitis & Psoriasis: Types: Anterior, Intermediate & Posterior. Further qualified as Acute (duration < 3 months), recurrent (repeated episodes separated by a period of 3 months or more without treatment), or chronic (duration > 3 months relapses within three months of stopping treatment). See the table below for specific etiologies. Acute Anterior variety causes pain & photophobia, decreased vision (due to corneal and macular edema), a prominent feature with a red eye, iris adhesions to the lens, and peripheral cornea. Keratin Precipitates are seen on slit-lamp examination of the eye. Chronic anterior uveitis presents with milder symptoms. Intermediate uveitis is painless and presents with floaters. Posterior uveitis is again painless and presents with varying degrees of visual loss. Posteriors can present with visual loss, chorioretinal vasculitis changes, etc. Posterior Uvea should also be assessed by ultrasound (USS), which shows choroidal thickening.¹⁸

Inflammatory Bowel Disease (IBD): can also co-exist in 5-10% of cases of PsA, and subclinical colitis may be present in some 30-40%¹⁴

Hyperuricemia is due to rapid skin cell turnover & is a feature of extensive skin psoriasis, so secondary gout may also be there.¹⁹

Diagnostic Criteria (CASPAR Criteria) & Activity Assessment

Inflammatory arthritis (any pattern) PLUS three or more of the following is needed for diagnosing psoriatic arthritis. Current Psoriasis scores 2 points, whereas other points score 1. Past or family history will not score any point if the patient has current Psoriasis.²⁰⁻²⁴ [Table 2 & 3].

Table 2: CASPAR Criteria for Psoriatic Arthritis
Inflammatory arthritis + three points from the following scoring system is needed to establish the diagnosis.

Criteria	Score
Current psoriasis In the patient	2
History of psoriasis (only if there is no current psoriasis)	1
Family history of psoriasis (only if there is no current psoriasis)	1
Psoriatic Nial Changes	1
Dactylitis	1
Juxta-articular new bone formation on X-rays	1
Negative RA factor	1

Treatment of Psoriatic Arthritis²⁵⁻³⁸

If there is no poor prognostic factor and the disease is

Table 3: GRAPA measures of minimal disease activity of Psoriasis.

Scoring 5 out of 7 points indicates minimal disease activity:

Tender joints	1 or less
Swollen Joints	1 or less
Psoriatic activity & Severity Index OR body surface area	1 or lesser less 3% or lesser
Patient pain visual analogue score	15 or lesser
Patient global disease activity visual analogue score	20 or lesser
Health assessment questionnaire	0.5 or lesser
Tender Enthesial points	1 or lesser.

mild/oligoarticular, NSAIDs can help. Intra-articular steroid injections (and sometimes systemic steroids) are used for symptom control. Systemic steroids increase the risk of arthritis (like pregnancy does too). Steroids also increase cutaneous relapse once stopped. Hence systemic steroids are not commonly used¹²⁵⁻³²¹. If any adverse prognostic factors are there, start synthetic chemical disease-modifying anti rheumatoid drugs csDMARD. These poor prognostic factors include >5 joints inflamed, moderate to severe disease, joint damage, functional impairment, or a history of steroid use. Methotrexate (MTX) (10-25 mg/week) works both for skin n joints. Leflunomide (Lef) 10-20 mg/day works only for joints, not skin. Sulfasalazine (SLZ) can be used for joints (2-3gm/day), isn't used for skin, and hydroxychloroquine (HCQ) can worsen skin lesions. Cyclosporine works well for joint & skin Psoriasis. But none of these prevent bone changes from causing joint damage. These also don't work for Spondylitis, enthesitis, or dactylitis.³³⁻³⁴

Axial disease, enthesitis, Dactylitis, or failure of csDMARD needs biological drugs such as TNFi. Anti-TNF drugs (especially Adalimumab & infliximab) are effective for joint disease, skin involvement, Dactylitis, or enthesitis. Abatacept works well for joints but not for skin. Abatacept, Tocilizumab, Tofacitinib, and rituximab (RTX) are other drugs that work when TNFi is ineffective or can't be used.³⁵⁻³⁸

The following drugs work for Psoriasis but not for RA;

- Apremilast, a phosphodiesterase-4 inhibitor (PDE-4 inhibitors) 20 mg BD or 40 mg OD, works well for skin and joints. Apremilast increases cAMP, which inhibits cytokines³³⁻³⁵¹.
- IL-17 blockers (Secukinumab, Ixekizumab) and IL23/12 blocker (Ustekinumab) works well for

skin and joints. These are alternatives for those who don't respond to TNFi etc. These drugs work better for Psoriasis as IL17 & IL12/23 have a significant role in Psoriasis (not for Rheumatoid Arthritis). TNF is common for both rheumatoid arthritis (RA) & Psoriasis. Dose of Ustekinumab is 45 (weight less than 100kg)- 90 mg (if weight more than 100 kg), subcutaneous (s/c) at 0 & 4 weeks, and then every three months.^{35,37,39,40}

Enthesitis or Dactylitis is treated with NSAIDs, Steroid injections, &/or biological (such as TNFi). Steroid injections for enthesitis can risk tendon rupture.^{27,33,36} Psoriatic Spondylitis is treated with NSAIDs & biological drugs such TNFi. csDMARD doesn't work for axial disease³¹⁻³⁵. Leflunomide & SLZ don't work for the skin. HCQ can make skin psoriasis worse. Abatacept doesn't work well for the skin. But Apremilast, IL12/23 inhibitors, & IL-17 blockers drugs work well for the skin. Topical treatment such as steroids, psoralen ultraviolet A (PUVA) /ultraviolet B (UVB), MTX, Cyclosporine, & biological (such as TNFi) is also used. A dermatologist manages skin psoriasis, and treatment choice depends on the extent, severity, and response to therapy.^{9-13,33-35}

Ustekinumab

Ustekinumab is a humanized monoclonal IgG1 antibody that targets the p40 part of IL-12 & IL-23. Hence, Ustekinumab blocks both and controls the inflammation, tissue damage, and new bone formation. Ustekinumab is approved for Psoriasis & PsA. It's especially useful when TNFi is not working. Also, it's a rapid-acting drug, more convenient to administer, and relatively safer than TNFi.^{39,40} The dose of Ustekinumab is 45 mg if bodyweight <100 kg or 90 mg if bodyweight is 100 kg or above. It's injectable given subcutaneously. A second dose follows the first dose at four weeks. Then third dose and the subsequent doses are given every 2-3 months. The dose can be increased to 90 mg and two months if the disease is resistant to a lesser dose. The convenience of subcutaneous injection and every three-monthly dose makes it more tolerable and acceptable.

Intracellular infections are the main risk as IL-12 & IL-23 are an important part of cell-mediated immunity. However, like other bDMARDs, screening, and prevention for tuberculosis (TB), hepatitis B virus (HBV), etc., is also recommended for Ustekinumab. There is no proven risk of heart failure, lymphoma, TB reactivation, autoimmune disease, or demyelination. This makes it safer than TNFi, which can cause all these side effects. Cancer risk is not well documented, but skin cancer reports. But long-term follow-up may clarify it further.

Conclusion

Psoriasis has variable clinical manifestations with signi-

ficant cosmetic effects, morbidity issues, and mortality. It can be confused with many skins and rheumatological diseases. It has differentiating clues to make a confident diagnosis. A detailed assessment is necessary to establish the diagnosis and extent of Psoriasis. Many effective treatment modalities are available to treat it. It's important to note that some drugs help joint disease but are ineffective for skin involvement. Some of the treatment options, such as MTX & anti-TNF, are similar to that used for rheumatoid arthritis. Still, additional options such as IL23/12 blocking biological agents and PDE-4 inhibitor drugs are also available and effective.

Conflict of Interest: *None*

Funding Source: *None*

References

1. Gladman DD, Antoni C, Mease P, Clegg DO, Nash P. Psoriatic arthritis: epidemiology, clinical features, course, and outcome. *Ann Rheum Dis*. 2005;64(2): 14-7.
2. Reich K, Krüger K, Mössner R, Augustin M. Epidemiology and clinical pattern of psoriatic arthritis in Germany: a prospective interdisciplinary epidemiological study of 1511 patients with plaque-type psoriasis. *Brit J Dermatol*. 2009;160(5):1040-7.
3. Rich P, Scher RK. Nail Psoriasis Severity Index: a useful tool for evaluation of nail psoriasis. *Am Acad Dermatol*. 2003;49(2):206-12.
4. Manhart R, Rich P. Nail psoriasis. *Clin Exp Rheumatol*. 2015;33(93):7-13.
5. Jiaravuthisan MM, Sasseville D, Vender RB, Murphy F, Muhn C.Y. Psoriasis of the nail: anatomy, pathology, clinical presentation, and a review of the literature on therapy. *J Am Acad Dermatol*. 2007;57(1):1-27.
6. Langenbach A, Radtke MA, Krensel M, Jacobi A, Reich K, Augustin M. Nail involvement as a predictor of concomitant psoriatic arthritis in patients with Psoriasis. *Br J Dermatol*. 2014;171(5):1123-8.
7. van der Velden HM, Klaassen KM, van de Kerkhof PC, Pasch MC. The impact of fingernail psoriasis on patients' health-related and disease-specific quality of life. *Dermatology*. 2014;229(2):76-82.
8. Elkayam O, Ophir J, Yaron M. Psoriatic arthritis: interrelationships between the skin and joint manifestations related to the onset, course, and distribution. *Clin Rheumatol* 2000;19(3):301-5
9. Martin BA, Chalmers RJ, Telfer NR. How great is the risk of further Psoriasis following a single episode of acute guttate Psoriasis? *Arch Dermatol*. 1996; 132(6): 717-8
10. Sontheimer RD. Skin manifestations of systemic autoimmune connective tissue disease: diagnostics and therapeutics. *Best Pract Res Clin Rheumatol*. 2004; 18(3):429-62.

11. Griffiths CE, Christophers E, Barker JN, et al. classification of psoriasis vulgaris according to phenotype. *Br J Dermatol.* 2007;156(2):258-62.
12. Schäfer T. Epidemiology of psoriasis. Review and the German perspective. *Dermatology* 2006;212(3): 327-37.
13. Gladman DD, Helliwell PS, Khraishi M, Duffin KC, Mease PJ. Dermatology screening tools: project update from the GRAPPA 2012 annual meeting. *J Rheumatol.* 2013;40(1):1425-7.
14. Gisondi P, Tinazzi I, El-Dalati G, Gallo M, Biasi D, Barbara LM, Girolomoni G. Lower limb enthesopathy in patients with psoriasis without clinical signs of arthropathy: a hospital-based case-control study. *Ann Rheum Dis.* 2008;67(1):26-30.
15. Haroon M, Kirby B, FitzGerald O. High prevalence of psoriatic arthritis in patients with severe psoriasis with suboptimal performance of screening questionnaires. *Ann Rheum Dis.* 2013;72(5):736-40.
16. McHugh NJ, Balachrishnan C, Jones SM. Progression of peripheral joint disease in psoriatic arthritis: a 5-yr prospective study. *Rheumatol.* 2003;42(6):778-83.
17. Coates LC, Conaghan PG, Emery P, Green MJ, Ibrahim G, MacIver H, Helliwell PS. Sensitivity and specificity of the classification of psoriatic arthritis criteria in early psoriatic arthritis. *Arthritis Rheum.* 2012; 64(10): 3150-5.
18. Queiro R, Torre JC, Belzunegui J, González C, De Dios JR, Unanue F, Figueroa M. Clinical features and predictive factors in psoriatic arthritis-related uveitis. *In Seminars Arthr Rheumatism.* 2002;31(4):264-270.
19. Mallbris L, Ritchlin CT, Ståhle M. Metabolic disorders in patients with psoriasis and psoriatic arthritis. *Curr Rheumatol Rep.* 2006;8(5):355-63.
20. Gladman DD. Disability and quality of life considerations. *Psoriatic arthritis. Psoriatic and psoriatic arthritis: an integral approach.* Heidelberg: Springer-Verlag. 2005:118-23.
21. Palazzi C, Lubrano E, D'ANGELO SA, Olivieri I. Beyond early diagnosis: occult psoriatic arthritis. *J Rheumatol.* 2010;37(8):1556-8.
22. Taylor W, Gladman D, Helliwell P, Marchesoni A, Mease P, Mielants H. Classification criteria for psoriatic arthritis: development of new criteria from a large international study. *Arthritis & Rheumatism: Official J Am Col Rheumatol.* 2006;54(8):2665-73.
23. Coates LC, Fransen J, Helliwell PS. Defining minimal disease activity in psoriatic arthritis: a proposed objective target for treatment. *Ann Rheumat Dis.* 2010; 69 (01):48-53.
24. Coates LC, Aslam T, Al Balushi F, Burden AD, Burden-The E, Caperon AR, Cerio R, Chattopadhyay C, Chinoy H, Goodfield MJ, Kay L. Comparison of three screening tools to detect psoriatic arthritis in patients with psoriasis (CONTEST study). *Br J Dermatol.* 2013;168(4):802-7.
25. Mallbris L, Ritchlin CT, Ståhle M. Metabolic disorders in patients with psoriasis and psoriatic arthritis. *Curr Rheumatol Rep.* 2006;8(5):355-63.
26. Kingsley GH, Kowalczyk A, Taylor H, Ibrahim F, Packham JC, McHugh NJ, Mulherin DM, Kitis GD, Chakravarty K, Tom BD, O'keeffe AG. A randomized placebo-controlled trial of methotrexate in psoriatic arthritis. *Rheumatol.* 2012;51(8):1368-77.
27. Behrens F, Finkenwirth C, Pavelka K, Stofla J, Sipek-Dolnicar A, Thaçi D, Burkhardt H. Leflunomide in psoriatic arthritis: results from a large European prospective observational study. *Arth Care Res.* 2013; 65(3): 464-70.
28. Sakellariou GT, Sayegh FE, Anastasilakis AD, Kapetanios GA. Leflunomide addition in patients with articular manifestations of psoriatic arthritis resistant to methotrexate. *Rheumatol Int.* 2013;33(11):2917-20.
29. Mease PJ, Fleischmann R, Deodhar AA, Wollenhaupt J, Khraishi M, Kielar D, Woltering F, Stach C, Hoepken B, Arledge T, Van Der Heijde D. Effect of certolizumab pegol on signs and symptoms in patients with psoriatic arthritis: 24-week results of a Phase 3 double-blind randomised placebo-controlled study (RAPID-PsA). *Ann Rheum Dis.* 2014;73(1):48-55.
30. Fenix-Caballero S, Alegre-del Rey EJ, Castaño-Lara R, Puigventós-Latorre F, Borrero-Rubio JM, López-Vallejo JF. Direct and indirect comparison of the efficacy and safety of adalimumab, etanercept, infliximab and golimumab in psoriatic arthritis. *J Clin Pharm Ther.* 2013; 38(4):286-93.
31. Goulabchand R, Mouterde G, Barnette T, Lukas C, Morel J, Combe B. Effect of tumour necrosis factor blockers on radiographic progression of psoriatic arthritis: a systematic review and meta-analysis of randomised controlled trials. *Ann Rheum Dis.* 2014; 73(2): 414-9.
32. D'Angelo S, Palazzi C, Olivieri I. Psoriatic arthritis: treatment strategies using biologic agents. *Reumatismo.* 2012;64(2):113-21.
33. Adebajo, A. O. et al. Long-term 52-week results of PALACE 1, a phase 3, randomized, controlled trial of apremilast, an oral phosphodiesterase inhibitor, in patients with psoriatic arthritis. *Rheumatology* 53 (Suppl. 1), i141 (2014).
34. Adebajo AO, Kavanaugh A, Mease PJ, Wollenhaupt J, Hu C, Shah K, Stevens RM, Gomez-Reino JJ. 217. Long-Term 52-Week Results of Palace 1, A Phase 3, Randomized, Controlled Trial of Apremilast, an Oral Phosphodiesterase Inhibitor, In atients with Psoriatic Arthritis. *Rheumatol.* 2014;53(1):i141-.
35. Deeks ED. Apremilast: a review in Psoriasis and psoriatic arthritis. *Drugs.* 2015;75(12):1393-403.
36. Coates LC, Navarro-Coy N, Brown SR, Brown S, McParland L, Collier H, Skinner E, Law J, Moverley A, Pavitt S, Hulme C. The TICOPA protocol (TIGHT Control of Psoriatic Arthritis): a randomised controlled trial to compare intensive management versus standard care in early psoriatic arthritis. *BMC Musculosk Dis.* 2013;14(1):1-8.

37. Coates LC, Tillett W, Chandler D, Helliwell PS, Korendowych E, Kyle S, McInnes IB, Oliver S, Ormerod A, Smith C, Symmons D. The 2012 BSR and BHPR guideline for the treatment of psoriatic arthritis with biologics. *Rheumatol*. 2013;52(10):1754-7.
38. Smolen JS, Braun J, Dougados M, Emery P, FitzGerald O, Helliwell P, Kavanaugh A, Kvien TK, Landewé R, Luger T, Mease P. Treating spondyloarthritis, including ankylosing spondylitis and psoriatic arthritis, to target: recommendations of an international task force. *Ann Rheum Dis*. 2014;73(1):6-16.
39. McInnes IB, Kavanaugh A, Gottlieb AB, Puig L, Rahman P, Ritchlin C, Brodmerkel C, Li S, Wang Y, Mendelsohn AM, Doyle MK. Efficacy and safety of ustekinumab in patients with active psoriatic arthritis: 1 year results of the phase 3, multicentre, double-blind, placebo-controlled PSUMMIT 1 trial. *Lancet*. 2013; 382(9894):780-9.
40. Patel DD, Lee DM, Kolbinger F, Antoni C. Effect of IL-17A blockade with secukinumab in autoimmune diseases. *Ann Rheum Dis*. 2013;72(2):116-23.