

Case Report

Dancing Movements Due to Endocrine Deficiencies: A Case Report

Maryam Haroon

Postgraduate Resident, Services Hospital Lahore

Abstract

Choreiform-ballistic movements have often been associated with lesions in basal ganglia and sub-thalamic nucleus. For a patient with dancing movements, hyperglycemia might be an initial presentation. We report a rare case of 19 years old Asian girl who had type I diabetes mellitus and Developed choreiform-ballistic type movements. She had ketoacidosis secondary to uncontrolled hyperglycemia along with hypocalcaemia secondary to either pseudo hypoparathyroidism???. On CT brain plain basal ganglia were heavily calcified. We optimized her diabetes management along with calcium and vitamin D analogues (calcitriol or alfacalcidol) and her symptoms got improved dramatically without using any specific antidopaminergic therapy or nerve stabilisers. Adults with mixed endocrine deficiencies can present with unique symptoms like choreiform-ballistic type movements that can be improved with exogenous administration/replacement of deficient hormones' analogues like in above mentioned case with insulin as well as calcium and vitamin D analogues supplementation.

Keywords: Choreiform movements, intact parathormone level (iPTH), ballistic movements, pseudo hypoparathyroidism, type I diabetes mellitus, basal ganglia, sub-thalamus nuclei, caudate and lenticular, exogenous.

How to cite this:

Haroon M. Dancing Movements Due to Endocrine Deficiencies. A Case Report. J Pak Soc Intern Med. 2022;3(3):250-252

Corresponding Author: Dr. Maryam Haroon

DOI: <https://doi.org/10.70302/jpsim.v3i3.2250>

Email: ezamaryam911@gmail.com

Introduction

Evaluating patients presenting to the emergency department with abnormal movements could be challenging. Dancing movements like choreiform or ballistic type are more common than hypo kinetic disorders. The clinical presentation can be acute or insidious, characterized by purposeless, irregular and involuntary jerky movements of extremities accompanied by facial grimacing. Chorea/ballismus/hemi-ballismus have often been associated with lesions in basal ganglia (caudate and lenticular nucleus) and sub-thalamic nuclei. Possible for a patient with chorea-ballismus to have hyperglycemia at initial presentation along with underlying hypocalcaemia secondary to endocrine deficiencies or hormones specific receptor abnormalities. We present a case of 19 years old girl who was on insulin therapy and presented with sub acute onset of abnormal movements of her right upper limb with predominant involvement of hand. Laboratory parameters showed derangement in total body calcium and glucose homeostasis milieu, originating as rare but unique hyper-kinetic movements disorder so called dancing movements. These movements can be either inherited, acquired secondary to metabolic/biochemical disorders, iatrogenic or immune mediated. This case report highlights the possibility of

mixed endocrine deficiencies as a cause of choreiform-ballistic type movements along with emphasizing improvement in symptoms control on substituting deficient hormones' analogues for example calcium supplements and vitamin D analogue besides injection insulin administration in present case.

Case presentation

Written informed consent was obtained from the patient's legal guardian for publication of this manuscript and accompanying images. A copy of the written consent is available for review by the Editor-in-Chief of the respected journal. A 19-years-old Asian girl presented in emergency department of our hospital with isolated abnormal movements of her right upper limb from last few hours. She was type I diabetic from last 7 years and compliant to insulin regime but history of often having dietary non compliance and behavioral changes. At presentation her vital signs were normal except RR 28 breaths/min, random blood sugar level 545mg/dl, thin lean with body weight 50 kg, height 5ft and 2 inches, well cooperated, oriented to time and space with involuntary, rapid, flying/dancing movements restricted to right sided upper limb. Her general and systemic examinations including neurological examination (cerebellum and dorsal column) were unremarkable. No

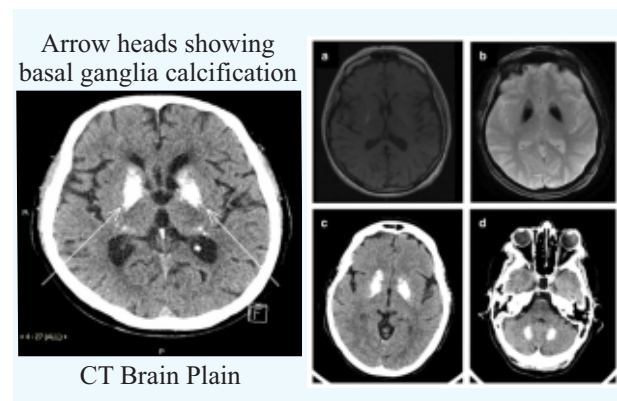
history of delayed milestones, congenital anomalies, inherited disorders or hormonal problems. Arterial blood gases showed PH: 7.106, PCO₂:20, PO₂:85, HCO₃: 8. The complete blood count revealed Hb 11, WBCs 8, PLTs 200. Creatinine: 0.9, serum Na: 135 mEq/L, serum K:5.0, serum calcium: 6.0, serum PO₄: 4.2, serum chloride: 102, serum Mg²⁺:2.4, AST: 20, ALT: 15, Bilirubin: 0.4, ALP: 135.

On urine complete exam PH: 5.8, pus cells: 2-3, Sp gravity: 1.020, ketones: +++, cast/crystals/ organisms: nil.

ECG, chest X-ray and ultrasound abdomen and pelvis were normal.

CT brain was performed and findings were consistent with hyper intensities likely calcification at the level of basal ganglia (Para-thalamic areas). Fluid resuscitation started with potassium replacement in accordance with DKA protocols, insulin infusion given at standard dose (wt. adjust). DKA got improved but dancing movements persisted. Meanwhile calcium gluconate administered intravenously and oral vitamin D analogue (alfacalcidol) supplementation started without nerve stabilizers (tetrabenazines). Within a day, her choreiform-ballistic movements got relieved, more necessary workup planned and patient was discharged. A follow up meeting was arranged with important labs. MRI brain with contrast further ruled out atrophic or neuro degenerative changes as well as SOL as a cause of these dancing movements.

Serum intact PTH: 150pg/ml (normal range 10-55p). Though suspicion of pseudohypoparathyroidism was on top of the list but genetic screening or studies were not available in our setup so urinary phosphate excretion along with urinary cyclic AMP were measured in response to intravenous recombinant PTH analogue administration and surprisingly mild phosphate excretion were detected in subsequent urinary samples.



Brain MRI showing T1-w hyperintensity in basal ganglia (a) and severe T2-GRE hypointensities in the same regions (b)*

Discussion

Dancing (choreiform-ballismus) movements are characterized by spontaneous involuntary movements, muscular weakness and uncoordinated movements. Can be classified as idiopathic, hereditary or acquired.¹ These movements can be caused by metabolic, vascular or structural disorders, hypoxic-ischemic events. Can be infection or drug induced or immune mediate affecting basal ganglia and sub thalamic nuclei. Such movements may be the presenting feature of endocrine deficiencies.² hyperglycemia may be present at initial presentation³, sometimes in association with underlying problems in other hormones milieu most commonly thyroid and parathyroid systems.⁴ The pathogenesis of choreiform-ballistic type movements with ketotic hyperglycemia along with pseudo hypoparathyroidism is poorly understood. In DKA, ketones specially acetoacetate is rapidly deleted leading cellular dysfunction⁵, also deposition of calcium in cerebral gray nuclei triggers functional impairment of inhibitory pathways of basal ganglia responsible for making body movements to be voluntary and refined.⁶ Prognosis of such movements is excellent.⁷ when mixed deficiencies are detected and subsequently corrected, dancing movements usually resolved within days without use of dopamine receptors antagonists.⁸ In this case report, patient hyperkinetic annoying choreiform movements resolved dramatically after treatment DKA secondary to uncontrolled hyperglycemia with simultaneous administration of calcium and vitamin D analogue. This illustrate that acute choreiform-ballistic type movement disorder is treatable one with excellent prognosis if compliance to treatment is assured. In patients with chorea-ballismus/hemi-ballismus with ketotic hyperglycemia in primary diabetes mellitus, CT and MRI images show either unilateral or bilateral caudate-lenticular nuclei lesions related to petechial hemorrhage or demyelination. However in our patient CT head revealed basal ganglia calcification. Thus serum glucose as well as serum calcium should be measured in all patients with new onset of choreiform-ballistic movements as they both are reversible cause of extra pyramidal movements disorder.

Conclusion

Choreiform movements are unique but rare manifestations of changes in hormonal milieu. In young patients hyperglycemia secondary to insulin deficiency can be an initial presentation associated with abnormalities in functioning of other endocrine organs that is parathyroid etc, however symptoms get improved with appropriate replacement of deficient hormones.

Conflict of Interest: None

Funding Source: None

References

1. Hashimoto KI, Ito Y, Tanahashi H, Hayashi M, Yamakita N, Yasuda K. Hyperglycemic chorea-ballism or acute exacerbation of Huntington's chorea? Huntington's disease unmasked by diabetic ketoacidosis in type 1 diabetes mellitus. *J Clin Endocrinol Metabol.* 2012; 97(9):3016-20.
2. Cleveland Clinic. Chorea. [updated 2020, cited July 2022] Available from: [<https://my.clevelandclinic.org/health/diseases/21192-chorea>]
3. Insogna KL. Primary hyperparathyroidism. *New Eng J Med.* 2018;379(11):1050-9.
4. Coppin EM, Roos RA. Current pharmacological approaches to reduce chorea in Huntington's disease. *Drugs.* 2017;77(1):29-46.
5. Piret SE, Thakker RV. Mouse models for inherited endocrine and metabolic disorders. *J Endocrinol.* 2011; 211(3):211-30.
6. Maiti A, Chatterjee S. Neuropsychiatric manifestations and their outcomes in chronic hypocalcaemia. *J Indian Med Assoc.* 2013;111(3):174-7.
7. Ferri FF, editor. *Ferri's Clinical Advisor 2022*, E-Book. Elsevier Health Sciences; 2021 Jun 9.
8. Patki R, Douglas R, Rimareva N, Kondamudi N. Uncontrollable movements of right upper and lower extremities in a child: A diagnostic puzzle. *J Am Col Emerg Physic Open.* 2021;2(4):e12497.