

Case Report

Cannabis Abuse and Cerebral Venous Sinus Thrombosis (CVST) in Male Patients

Mazhar Hamdani, Abdul Khalid, Ayesha Ishaq, Muhammad Arshad

Abbas Institute of Medical Sciences, AJK Medical College, Muzaffarabad

Abstract

Cannabis is among the most commonly used psychoactive substance in the world¹. Smoking Cannabis is common in the cultural events of Sub-Continent and some visitors smoke it over shrines during the festivals. A 37- years old male, married, driver by profession, the only earner of his family with three dependents, presented in emergency department (ED) in January 2022 with severe, diffuse, thunderclap and non-resolving headache for the last two days. He used oral diclofenac sodium for one day without medical advice and there was no improvement in the headache. He was a smoker and also smoked cannabis during last one month and smoked cannabis in amounts more than his usual routine. On examination, his blood complete picture showed TLC 11.7×10^3 /cubic millimeter (cmm), Hb.15.3 gm/dl, PLT 180×10^3 / cmm, total bilirubin 1.2 mg/dl, ALP 260 U/L, ALT 39 U/L, Urea 36 mg/dl, Creatinine 0.8 mg/dl and erythrocyte sedimentation rate was 30 mm in 1st hour. He was treated with Enoxaparin, Tramadol and Metoclopramide. Naproxen Sodium and Normal Saline were given on day one only. Patient significantly improved after 5 days of treatment and was discharged on direct oral anticoagulants.

How to cite this:

Hamdani M, Khalid A, Ishaq A, Arshad M. Cannabis Abuse and Cerebral Venous Sinus Thrombosis (CVST) in male patients. J Pak Soc Intern Med. 2023;4(2): 145-148

Corresponding Author: Dr. Abdul Khalid

DOI: <https://doi.org/10.70302/jpsim.v4i2.2330>

Introduction

Cannabis is among the most commonly used psychoactive substance in the world¹. Smoking Cannabis is common in the cultural events of Sub-Continent and some visitors smoke it over shrines during the festivals. The two most active cannabinoids present in cannabis, delta-9-tetrahydrocannabinol (THC) and cannabidiol (CBD) create a sense of euphoria, tranquility and relaxation². The other significant effects are cognitive dysfunction, impaired memory and inability to perform executive functioning³. A systematic review concluded that there is comparatively higher prevalence of ischemic stroke and hemorrhagic stroke in people with cannabis use⁴. There might be an association of cannabis intake with unprovoked Cerebral Venous Sinus Thrombosis (CVST) occurrence in male patients. The CVST is a type of rare stroke which is more common in young females. It is a serious, potentially fatal cause of stroke that can be misdiagnosed and overlooked due to its vague clinical presentations and radiological features. We report two cases of cannabis abuse associated with cerebral venous sinus thrombosis. These cases of CVST have been reported in male visitors of a shrine at Muzaffarabad during a famous festival where cannabis

Email: abdulkhalid301@gmail.com

is abused freely. These patients presented in the Abbas Institute of Medical Sciences Muzaffarabad Azad Kashmir in January, 2022.

Case Presentation

A 37- years old male, married, driver by profession, the only earner of his family with three dependents, presented in emergency department (ED) in January 2022 with severe, diffuse, thunderclap and non-resolving headache for the last two days. He used oral diclofenac sodium for one day without medical advice and there was no improvement in the headache. The next day, he reported to hospital Emergency Department. The rest of systemic inquiry was unremarkable and his past medical and surgical history was not significant. He was a smoker and also smoked cannabis during last one month. The exact amount of cannabis smoked daily was not known. He recently attended a local festival where he smoked cannabis in amounts more than his usual routine. He was vaccinated for covid-19 six months back.

On examination, a healthy adult male of average height and built, sick looking, distressed with severe pain, conscious, oriented, alert with fair hydration status. His Pulse was 88/min, Blood Pressure 140/90 mmHg in supine position, Temperature 97°F and Respiratory

Rate was 18/min. His GCS of 15/15 and there were no signs of meningeal irritation, pupils were bilateral equal and reactive to light and fundoscopy was normal. The examinations of cranial nerves, motor and sensory systems were also normal. The rest of the systemic examination was unremarkable. His blood complete picture showed TLC 11.7×10^3 /cubic millimeter (cmm), Hb.15.3 gm/dl, PLT 180×10^3 / cmm, total bilirubin 1.2 mg/dl, ALP 260 U/L, ALT 39 U/L, Urea 36 mg/dl, Creatinine 0.8 mg/dl and erythrocyte sedimentation rate was 30 mm in 1st hour. His serum electrolytes, thrombophilic Profile were normal and Anti-Nuclear Antigen was negative. The D-Dimers were 800 IU, Covid-19 PCR was negative. The Plain CT scan of the brain showed dense transverse venous sinus on right side compatible with the diagnosis of transverse venous sinus thrombosis. CT Venogram or MRV not done due to non-affordability of the patient. He was treated with Enoxaparin 60 IU Sub-Cutaneous 12 hourly, Inj. Tramadol and Metoclopramide IV SOS, Tab. Naproxen Sodium 500 mg PO 12 hourly and IV Normal Saline 1000 ml on day one only. Patient significantly improved after 5 days of treatment and was discharged on direct oral anticoagulants with advice to follow up in Neurology OPD after one week.

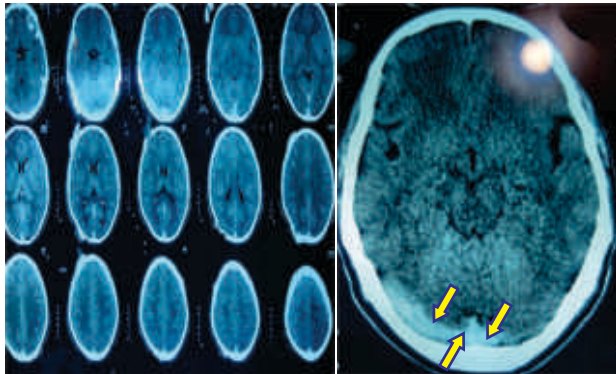


Figure 1: CT Scan of Patient showing Hyperdense trans-Venous Sinus (Yellow Arrows) on Right Side.

Case 2

A 50 -years old male, married, resident of Muzaffarabad presented via ER in January 2022 with no known comorbidities with chief complaints of vertigo for the last five days and two episode of vomiting on day of presentation followed by drowsiness. According to patient's wife, he was in his usual state of health one week back then he developed vertigo and dizziness after coming from the cultural event notorious for cannabis abuse. Patient consulted his primary physician who prescribed him meclizine and beta histidine for three days with no improvement in the symptoms. He was brought in ED of Abbas Institute of Medical Sciences Muzaffarabad

after an episode of vomiting followed by drowsiness. He had normal appetite, bowel and bladder habits, sleep pattern and had no other systemic symptoms. There was no significant past medical or surgical history and he had covid -19 vaccination four months ago. There was no history of allergies and blood transfusions however, he had history of cannabis abuse during that week. On examination he was drowsy and sick looking, his GCS was 8/15, no specific breathing pattern and no signs of meningeal irritation. There were bilateral constricted pupils reactive to light, equal body movements bilaterally on painful stimuli and Planters were mute. His fundoscopy showed bilateral papilledema. Chest auscultation revealed fine crackles at right lower chest. The rest of systemic examination was unremarkable. He was admitted as a case of aspiration pneumonia and suspected case of stroke in ICU. His complete blood picture showed TLC 10.1×10^3 /cmm, Hb.16.2 gm/dl, PLT 150×10^3 / cmm, Prothrombin time 14/15 sec, partial thromboplastin time 33/34 sec, total Bilirubin 1.1mg/dl, ALP 200 U/L and ALT was 31 U/L. The Blood Urea was 34 mg/dl, Creatinine 0.7 mg/dl, erythrocyte sedimentation rate 28 mm in 1st hour, while serum electrolytes, D-Dimers and ECG were normal. Cerebrospinal fluid routine examination showed clear fluid with normal pressure, Cells $5/\text{mm}^3$, Glucose 67 mg/dl (against 98 mg/dl BSR), Protein 50 mg/dl. Arterial blood gases showed High anion metabolic acidosis. His toxicology screening revealed high levels of cannabinoids and benzodiazepines in urine. His Chest x-ray and CT scan brain were normal. COVID RT PCR was negative. CSF for Viral serology, fungal panel, bacterial panel including, Gene-Xpert for mycobacterium tuberculosis, autoimmune and paraneoplastic panel were also normal. He was initially managed as a suspected case of meningo-encephalitis and broad-spectrum antibiotics and antivirals were started with the prophylactic dose of Enoxaparin, IV fluids and flumazenil were also given. There was no clinical improvement in the conscious level and his respiratory rate increased, GCS dropped to less than

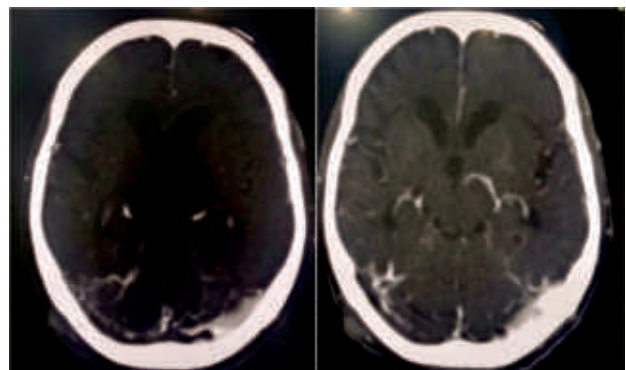


Figure 2: CT Venogram of patient showing sinus thrombosis in right transverse and sigmoid sinus and left transverse sinus

6/15 and pupils were still constricted. The patient developed generalized tonic-clonic fits and he was put on ventilatory support. But despite all measures there was no improvement in his condition. Then CT scan brain was repeated and venogram was done which showed right transverse and sigmoid sinus up to internal jugular and left proximal transverse sinus thrombosis. Enoxaparin dose increased from 40 mg to therapeutic range 60 mg subcutaneous twice daily with IV levetiracetam, ventilator mode settings by anesthesia team to decrease intracranial pressure.

Discussion

Cerebral venous thrombosis is a potentially fatal condition as it is sometimes difficult to diagnose due to its nonspecific clinical features and protean presentations⁵. The clinical presentation is often variable and depends upon the site of the lesion, age of patient, extent of thrombosis and different underlying etiological factors⁶. These factors lead to an average delay of 3 days from admission to diagnosis of CVST⁷. The most common presentations are due to the raised intra cranial pressure i.e. headache, vomiting, papilledema, fits, focal signs and diffuse encephalopathy⁸. The other less common presentations are thunderclap headache, tinnitus and multiple cranial nerve palsies⁹. A high degree of suspicion and appropriate clinical acumen is required to diagnose CVST along with neuro-imaging as a gold standard modality to confirm the diagnosis¹⁰. Owing to the rarity and difficulty in diagnosis of the disease, many underlying risk factors and natural course of disease is yet to be identified. The Cannabinoids are highly lipid soluble compounds that readily absorb and dissolve into blood after being smoked¹¹. These compounds can easily cross the blood brain barrier and get deposited in highly perfused areas of body like heart, lungs and brain. They also reduce the brain blood flow by increasing cerebrovascular resistance and systolic velocity. In the periphery cannabinoids decrease the para-sympathomimetic tone in the body causing vasodilation and orthostatic hypotension consequently leading to syncopal attacks, further compromising the cerebral blood flow¹². Furthermore, the long term cannabis use has been associated with structural changes in brain too¹³. Therefore, we postulate that these mechanisms could be the possible mechanism of cerebral venous thrombosis in these patients. Cannabis one to three grains contain 65 to 195 mg of the drug, the relatively higher quantity than usual taken during the cultural festival where it is available free of cost as tradition, might be the cause of cerebral venous sinus thrombosis in these patients.

CVST is the rare form of Stroke occurs more commonly in females due to obstetric complications, OCP use and during puerperium¹⁴. However, it is extremely rare to

see male patient with CVST in this region. The presentation of two male patients during same time frame of the year, with previous exposure of cannabis as a common thing is unlikely to be a co-incidence. The clinical suspicion of cannabis as the underlying etiology of CVST in both cases was extremely high. There's no literature review about this association previously but we suspect that there's a link between cannabis abuse and cerebrovascular sinus thrombosis in male gender due to perhaps some mechanism that is yet to be identified.

Conflict of Interest *None*

Funding Source *None*

References

1. United Nations Office on Drugs and Crime. World Drug Report. Executive Summary. Conclusions and Policy Implications (2018)
2. Sorkhou M, Bedder RH, George TP. The behavioral sequelae of cannabis use in healthy people: a systematic review. *Front Psychiat*. 2021;12(1):630247.
3. Panlilio LV, Ferré S, Yasar S, Thorndike EB, Schindler CW, Goldberg SR. Combined effects of THC and caffeine on working memory in rats. *Br J Pharmacol*. 2012;165(12):2529–38.
4. Swetlik C, Migdady I, Hasan LZ, Buletko AB, Price C, Cho SM. Cannabis Use and Stroke: Does a Risk Exist? *J Addict Med*. 2022;16(2):208-15.
5. García-Azorín D, Monje MH, González-García N, Guerrero ÁL, Porta-Etessam J. Presence of red flags in patients with cerebral venous sinus thrombosis admitted to the emergency department because of headache: A STROBE compliant cohort-study. *Medicine*. 2020;99(29):(e20900).
6. Dentali F, Poli D, Scoditti U, et al. Long-term outcomes of patients with cerebral vein thrombosis: a multicenter study. *J Thromb Haemostasis*. 2012;10(5):1297–302.
7. Ferro JM, Canhão P, Stam J, Bousser MG, Barinagarrementeria F. Prognosis of cerebral vein and dural sinus thrombosis. Results of the international study on cerebral vein and dural sinus thrombosis. *Stroke*. 2004;35(3):664–70.
8. Komro J, Findakly D: Cerebral venous sinus thrombosis in adults with prothrombotic conditions: a systematic review and a case from our institution. *Cureus*. 2020; doi:10.7759/cureus.7654.
9. Findakly D, Komro J. Not Just Another Headache: Cerebral Venous Sinus Thrombosis in a Patient With Isolated Antithrombin III Deficiency. *Cureus*. 2020;12(5):e8383. doi:10.7759/cureus.8383.
10. Luo Y, Tian X and Wang X. Diagnosis and treatment of cerebral venous thrombosis: a review. *Frontiers Aging Neurosci*. 2018;10(1):2.

11. Morgan CJ, Freeman TP, Hindocha C, Schafer G, Gardner C, Curran HV. Individual and combined effects of acute delta-9-tetrahydrocannabinol and cannabidiol on psychotomimetic symptoms and memory function. *Transl Psychiatry*. 2018; doi: 10.1038/s41398-018-0191-x.
12. Lowe DJ, Sasiadek JD, Coles AS, George TP. Cannabis and mental illness: a review. *Eur Arch Psychiatry Clin Neurosci*. 2019;269(1):107–20.
13. Becker MP, Collins PF, Schultz A, Urošević S, Schmalting B, Luciana M. Longitudinal changes in cognition in young adult cannabis users. *J Clin Exp Neuropsychol*. 2018;40(3):529–43.
14. Jonathan M. Coutinho, José M. Ferro, Patrícia Canhão. Cerebral Venous and Sinus Thrombosis in Women. *Stroke*. 2009;40(7):2356-61.