

## Case Report

## Hypoplastic Left Heart Syndrome

Asra Mariam,<sup>1</sup> Zaeem Ahmad,<sup>2</sup> Arif Hussain,<sup>1</sup> Nouman Nazeer,<sup>1</sup> Humaira Zia<sup>3</sup><sup>1</sup>Bahawal Victoria Hospital Bahawalpur, <sup>2</sup>Mayo Hospital Lahore, <sup>3</sup>Holy Family Hospital Rawalpindi**Abstract**

Hypoplastic left heart syndrome (HLHS) is a congenital heart disease characterized by varying degrees of underdevelopment of the heart's left side; this results in affected blood flow from the left half of the heart to the body. We report a case of three months old girl who presented to the outpatient department with symptoms of respiratory distress and cyanosis and was diagnosed as a case of HLHS on echocardiography. We discuss the epidemiology, clinical presentation, pathophysiology, risk factors, investigations and management of HLHS in brief.

**How to cite this:**

Mariam A, Ahmad Z, Hussain A, Nazeer N, Zia H. Hypoplastic Left Heart Syndrome; Case Report. J Pak Soc Intern Med. 2023;4(3): 240-243

**Corresponding Author:** Dr. Zaeem Ahmad

DOI: <https://doi.org/10.70302/jpsim.v4i3.2349>

**Introduction**

Hypoplastic left heart syndrome (HLHS) is a congenital heart disease characterized by various degrees of malformation of the heart's left side. The condition was first reported in 1951 by a German Pathologist Dr Bardeleben.<sup>1</sup> It was first described in 1952 by Lev who described it as hypoplasia of the aortic tract complex.<sup>2</sup> Later in 1958, Noonan and Nadas named it a syndrome characterized by the underdevelopment of the left-sided heart chambers associated with aortic and mitral atresia.<sup>1</sup> HLHS constitutes 2%-3% of all congenital heart diseases in the UK, but the incidence of the syndrome in Pakistan is still unknown. HLHS occurs in 3% of infants born with congenital cardiac defects and accounts for 25% to 40% of all deaths due to congenital heart defects.<sup>3</sup> The condition is fatal in the first two weeks of life in 95% of cases and, if left untreated, is uniformly fatal in 100% of cases.<sup>3,4</sup> The condition's distribution is independent of ethnic or geographic parameters, but there is evidence of 2:1 male dominance.<sup>3</sup>

The two major types of malformations include aortic atresia or mitral atresia, often associated with atrial septal defect (ASD) or ventricle septal defect (VSD).<sup>5</sup> The abnormalities involve hypoplasia of the aorta, left atrium, and/or left ventricle. 45% of cases are also associated with coarctation of the aorta.<sup>4</sup> As a result, the left heart cannot maintain systemic circulation resulting in right heart-dependent circulation either via ductus arteriosus, a wide foramen ovale, or co-existing ASD or VSD. This

**Email:** zaeem.ahmad344@gmail.com

left to right shunting of blood is the reason for cyanosis and pulmonary hypertension. Initially, the severity of symptoms could be hidden in infants due to patent ductus arteriosus. Closure of ductus arteriosus results in failure to maintain systemic circulation and eventually cardiac failure associated mortality.<sup>3,6</sup>

Before 1980 no long-term intervention was available for HLHS resulting in high mortality of infants born with the condition. In 1980, Norwood introduced the first palliative reconstructive surgical procedure for HLHS.<sup>1</sup> In 1986, the first infant heart transplant for HLHS was performed by Bailey providing an alternative solution for palliative surgery.<sup>7</sup> Although comfort care and active resuscitation options are still present, surgical intervention is necessary for survival beyond the neonatal period.

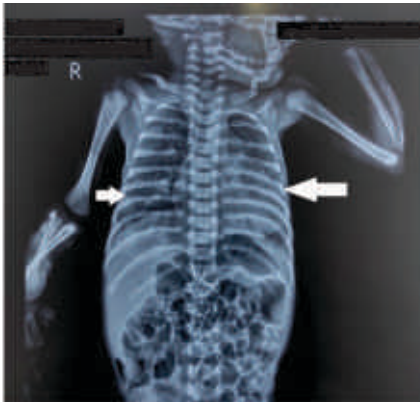
**Case Presentation**

A 3 months old girl presented to the outpatient department with complaints of severe respiratory distress, cyanosis, feeding aversion, diarrhea, and failure to thrive for two months. Her history was significant for recurrent episodes of cyanosis and respiratory tract infections since birth. Her mother was 26-year-old, gravida 4, para 3. The pregnancy and delivery of the child were uneventful. The antenatal visit records were not available, and the infant was delivered at home via spontaneous vagina delivery, at term and without induction of labor. Her birth weight was 2.5kg. Previous family history for HLHS was negative.

Initial physical examination revealed a lethargic child

with a bodyweight of 3.0kg. Her vital signs were within normal limits. She had central and peripheral cyanosis and +1 peripheral pulses. She exhibited visible indrawing of chest walls, a parasternal heave was present, and a thrill was perceived at the left lower sternal border. Her maximal impulse was displaced laterally, and she exhibited a loud S2 with fixed wide splitting. A holosystolic murmur was audible all over the precordium with maximum intensity at the left lower sternal border. The murmur was harsh, high-pitched, grade IV in intensity, and radiated to the right lower sternal border.

Baseline investigations were normal except Alanine Transaminase (ALT) of 45 IU/L and Alkaline phosphatase (ALP) of 250 IU/L. Chest X-ray revealed cardiomegaly with bilateral lung opacities (Figure.1). An echocardiogram revealed small ASD, two large perimembranous and mid-muscular VSDs, mitral atresia, small left ventricle, aortic valve, and severe coarctation of the aorta (Figure. 2). A diagnosis of HLHS was made based on an echocardiogram. She was treated empirically for pneumonia due to patchy lung opacities and referred to cardiology for HLHS management; however, she was lost to follow-up.



**Figure 1.** X-rays of the patient showing cardiomegaly and lung opacities



**Figure 2** Echocardiography report revealing mitral atresia, ASD, VSD, coarctation of aorta and small

sized left ventricle confirming the diagnosis of HLHS

### Discussion

The causes of HLHS are poorly understood and are believed to be multifactorial, involving maternal, gestational, genetic, and teratogenic factors. An alteration in blood flow patterns through the fetal heart during early embryonic life can be linked with the syndrome. So far, no specific genetic basis has been linked with HLHS. However, associations with chromosomal abnormalities like Down Syndrome and Turner Syndrome are found in 5% to 12% of the cases. The most common association is with Jacobson's Syndrome (11q deletion) in which the incidence of HLHS is up to 10%.<sup>3</sup>

HLHS is a cyanotic heart disease characterized by varying degrees of hypo-development of the heart's left side with the central element being atresia or stenosis of either mitral or aortic valve. The valvular atresia is associated with the sequential hypoplasia of left ventricle, ascending aorta and aortic arch which allows the inflow of blood but restricts outflow from the left heart. There outflow obstruction is divided into two categories – outflow obstruction from the left ventricle which mainly involved aortic valve atresia or stenosis and flow obstruction into the left ventricle, mainly involving mitral valve atresia or stenosis. The most common cause of development of HLHS is aortic valve atresia which causes an increase in left ventricular pressure. During early fetal life, aortic valve atresia causes increased afterload leading to dilation and hypertrophy of the left ventricle which appears normal in size. As the fetal size increases with gestational age, the reduced flow inhibits the left ventricular growth and it gradually becomes hypoplastic.<sup>1,5,6</sup>

The cardiac output is then maintained by the right ventricle's pumping action, which receives blood from left to right shunt via a patent foramen ovale or an ASD. Blood from right ventricle is pumped into the pulmonary trunk where it is divided in to pulmonary and systemic circulation. The pulmonary circulation is maintained by normally developed left and right pulmonary arteries. However, the systemic circulation is dependent on a patent ductus arteriosus which conduits blood to descending aorta. Thus, both pulmonary and systemic circulation is supported by a single right ventricle leading to the secondary hyperplasia of the right ventricle. The coronary circulation is provided by a retrograde flow of blood from ductus arteriosus to the hypoplastic ascending aorta.<sup>1,5</sup>

The systemic, cerebral and coronary circulation in fetus is well maintained owing to the high pulmonary vascular resistance favoring systemic and coronary channels. Thus, normal systemic and coronary perfusion is maintained during fetal life. However, a spontaneous decrease

in pulmonary vascular resistance and closure of ductus arteriosus after birth results in a significant compromise in the systemic circulation. Most of the cardiac output is relocated to the lungs due to decreased pulmonary vascular resistance. This is coupled with the failure of systemic, cerebral and even coronary circulation as ductus arteriosus closes. A combination of metabolic acidosis, hypoxia and ischemia ensues resulting in rapid mortality in the absence of treatment interventions.<sup>1,3,5</sup>

The clinical presentation of the condition varies in severity depending upon the morphology of the heart. The left to right shunt through Foramen Ovale or ASD is the only exit of blood from the left heart causing the mixing of systemic and pulmonary blood. As a result, typical arterial blood oxygen saturation is between 75% to 85% which is responsible for the presentation with cyanosis.<sup>5</sup> Severe symptoms are masked before the closure of ductus arteriosus. The presentation may include poor perfusion hypoxia, cyanosis, acidosis, weak pulses, hypotension and tachycardia which may lead to cardiogenic shock. However, 6% of the patients are born with intact inter-arterial septum.<sup>3</sup> These patients manifest severe symptoms at birth and have higher mortality rates. If diagnosed early, survival could be prolonged by surgical septostomy of the heart that maintains left to right shunt, stabilizing the patient until palliative surgery could be performed.<sup>8</sup>

The diagnostic investigation for HLHS is echocardiography in utero or after birth. Although most cases of HLHS are diagnosed after birth, the condition could also be diagnosed prenatally by fetal echocardiography between 18 to 24 weeks of gestation. However, in high-risk pregnancies, echocardiography should be repeated in 3<sup>rd</sup> trimester as the lesions are more prominent during the third trimester of pregnancy.<sup>3,8</sup>

Electrocardiogram (ECG) may reveal non-specific changes secondary to right ventricular hypertrophy.<sup>3</sup> A chest X-ray may reveal cardiomegaly along with pulmonary edema due to pulmonary venous hypertension. Blood work including complete blood count, arterial blood gas, electrolytes and lactate may be done to evaluate hematocrit and degree of acidosis, hypoxia and organ failure.<sup>5</sup>

Although HLHS is fatal if left untreated, the survival rates have been greatly improved in the last two decades with the introduction of palliative surgical techniques, which are the mainstay of treatment in HLHS.<sup>1</sup> The early and primary goal of management is to stabilize the patient until palliative surgery is performed. This is done by maintaining the patency of ductus arteriosus in neonates by intravenous prostaglandin E2 infusion.<sup>3,9</sup> Metabolic acidosis is corrected by infusing Sodium bicarbonate and arterial oxygen saturation is maintained by keeping the hematocrit between 40% to 45%.<sup>5</sup> In

patients with an intact interatrial septum, a Percutaneous Balloon Septostomy can be done early in life to maintain a wide ASD. Heart transplantation is another option but not preferred due to limitations including long-term immunosuppression, limited organ donors, and high mortality rates.<sup>9</sup>

The most common and successful treatment of HLHS is palliative surgery. The standard palliative procedure is the Norwood procedure which encompasses a three-step surgical procedure carried out at different ages. The procedure aims at separating the systemic and pulmonary circulations with right ventricle working as the systemic ventricle. Stage one is performed within a week after birth, stage two between 2-10 months, and stage three is carried out between 18-24 months of life.<sup>3,5,10</sup>

This is achieved by the following interventions:

- Atrial septectomy allows the blood from pulmonary veins to enter the right ventricle.
- Reconstruction of the aortic arch (neo-aorta) by constructing an anastomosis between the main pulmonary trunk and the hypoplastic ascending aorta.
- Shunting the main pulmonary artery with either subclavian or brachiocephalic arteries using a modified Blalock-Taussig (BT) shunt to maintain the pulmonary circulation.

The survival rate post-operatively is up to 95%. The long-term outcome of surgery is promising, and the quality of life is significantly better. Some concerns about neurological under-developments do exist, and patients require life-long medical follow-up.<sup>3</sup>

## Conclusions

We conclude that lack of prenatal visits and pregnancy education can result in undiagnosed or late diagnosis of HLHS, adding to its mortality. The diagnosis made after birth dramatically reduces the chance of survival due to delay in management and palliative measures. The unavailability of resources also adds to the mortality of infants with HLHS in Pakistan. Further long-term and comparative data are required to study epidemiology and outcomes of HLHS in underdeveloped countries with limited resources. It would be interesting to compare mortality and survival data with the western world as well.

**Conflict of Interest:** None

**Funding Source:** None

## References

1. Grossfeld P, Nie S, Lin L, Wang L, Anderson R: Hypoplastic Left Heart Syndrome: A New Paradigm for an Old Disease? J Cardiovasc Dev Dis. 2019; doi: 10.3390/jcdd6010010

2. Yabrodi M, Mastropietro CW: Hypoplastic left heart syndrome: from comfort care to long-term survival. *Pediatr Res.* 2017, 81:142–9. 10.1038/pr.2016.194
3. Barron DJ, Kilby MD, Davies B, Wright JG, Jones TJ, Brawn WJ. Hypoplastic left heart syndrome. 2009; p. 374.
4. Graupner O, Enzensberger C, Axt-Fliedner R: New Aspects in the Diagnosis and Therapy of Fetal Hypoplastic Left Heart Syndrome. *Geburtshilfe Frauenheilkd.* 2019;79(4):863-72. 10.1055/a-0828-7968
5. Kritzmire S, Cossu A: Hypoplastic Left Heart Syndrome. Treasure Island (FL): StatPearls Publishing; 2022. Available from: [<https://www.ncbi.nlm.nih.gov/books/NBK554576/>].
6. Gobergs R, Salputra E, Lubaua I: Hypoplastic left heart syndrome: a review. *Acta medica Lituanica.* 2016; 23 (2): 86.
7. Bailey LL: Transplantation is the best treatment for hypoplastic left heart syndrome. *Cardiol Young.* 2004, 14(1):109–11.
8. Fruitman DS: Hypoplastic left heart syndrome: Prognosis and management options. *Paediatr Child Health.* 2000, 5(2):219–25.
9. Ohye RG, Schranz D, D’Udekem Y: Current Therapy for Hypoplastic Left Heart Syndrome and Related Single Ventricle Lesions. *Circulation.* 2016, 134(6): 1265–79.
10. Norwood WI: Hypoplastic left heart syndrome. *Ann Thorac Surg.* 1991;52(3):688-95.